

# Posterior meniscal root injuries

## A comprehensive review from anatomy to surgical treatment

Gilbert MOATSHE<sup>1,2,4</sup>, Jorge CHAHLA<sup>1</sup>, Erik SLETTE<sup>1</sup>, Lars ENGBRETSSEN<sup>2</sup>, and Robert F LAPRADE<sup>1,3</sup>

<sup>1</sup> The Steadman Philippon Research Institute, Vail, CO, USA; <sup>2</sup> Orthopedic Department, Oslo University Hospital, Oslo, Norway; <sup>3</sup> The Steadman Clinic, Vail, CO, USA; <sup>4</sup> OSTRC, the Norwegian School of Sports Sciences, Oslo, Norway.

Correspondence: drlaprade@sprivail.org

Submitted 2016-01-11. Accepted 2016-05-09.

**ABSTRACT** — Meniscal root tears (MRTs) are defined as radial tears within 1 cm of the meniscal root insertion, or an avulsion of the insertion of the meniscus. These injuries change joint loading due to failure of the meniscus to convert axial loads into hoop stresses, resulting in joint overloading and degenerative changes in the knee. Meniscal root repair is recommended in patients without advanced osteoarthritis (Outerbridge 3–4), in order to restore joint congruence and loading and therefore to avoid the long-term effect of joint overloading. Several techniques have been described. Improved knee function has been reported after meniscal root repair, but there are still conflicting reports on whether surgical treatment can prevent osteoarthritis.

Meniscal root tears (MRTs) are defined as radial tears within 1 cm of the meniscus insertion, or avulsions at the insertion of the meniscus (Allaire et al. 2008, Marzo and Gurske-DePerio 2009). This injury leads to failure of the meniscus to convert axial loads into transverse hoop stresses (Allaire et al. 2008, Marzo and Gurske-DePerio 2009, Schillhammer et al. 2012, Padalecki et al. 2014, LaPrade et al. 2014a, Feucht et al. 2015b). The changes in joint loading lead to accelerated cartilage degeneration, with changes comparable to those seen following a total meniscectomy (Allaire et al. 2008). Extrusion of the medial meniscus has been observed in both partial and total meniscal root tears, with extrusion > 3 mm being associated with increased cartilage degeneration and osteophyte formation (Lerer et al. 2004).

Meniscal root tears may be acute or chronic. Posterior lateral meniscus root tears are associated with anterior cruciate ligament (ACL) tears (De Smet and Mukherjee 2008, Feucht et al. 2015a, 2015c), with one study reporting posterolateral meniscal root tears in 8% of ACL tears (De Smet and Mukher-

jee 2008). The etiology of posterior medial meniscus root tears is often degenerative, as seen in middle-aged women (Kim et al. 2011a, Hwang et al. 2012), but it can also be seen in an acute setting in association with multiple ligament knee injuries (Kim et al. 2010, Ra et al. 2015). Up to one-fifth of medial meniscal tears are found in the posterior root (Hwang et al. 2012). Matheny et al. (2015) reported that patients who had a lateral meniscus root tear were more likely to have an ACL tear, while patients with a medial meniscus root tear were more likely to have concomitant chondral defects. Iatrogenic meniscal root injuries have been described. Malposition of the ACL tibial tunnel during ACL reconstruction, and reaming for tibial shaft fractures can damage the anterior root of the meniscus (LaPrade et al. 2014b, LaPrade et al. 2015d, Ellman et al. 2015, Watson et al. 2015).

In recent years, there has been increasing interest in meniscal preservation because meniscectomy has been reported to increase the risk of osteoarthritis (Ozkoc et al. 2008, Han et al. 2010). The goal of meniscal root surgery is to restore joint congruence, meniscal integrity, and hoop stresses, thereby restoring joint mechanics and loading to prevent cartilage degeneration. Meniscectomy, partial meniscectomy, transosseous root repair, and suture anchor technique for meniscal root repair are the most commonly used surgical options. This review article provides a comprehensive review of posterior meniscal root injuries.

### Classification

There are currently 2 classification systems for meniscal root injuries. LaPrade et al. (2015b) developed a classification system for both medial and lateral posterior root tears based on tear morphology. There are 5 distinct lesions: partial stable root tear (type 1), complete radial tear within 9 mm of the root attachment (type 2), bucket-handle tear with complete

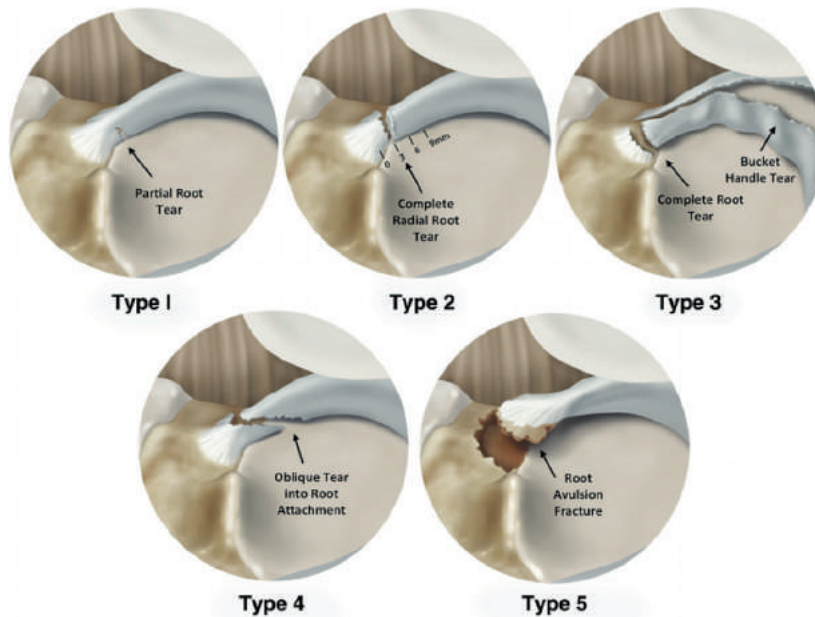


Figure 1. Illustrations of the meniscal root tear classification system in 5 different groups based on tear morphology. For consistency, all meniscal tears are shown as medial meniscal posterior root tears in this illustration. The classification of 5 tear patterns was based on morphology: partial stable root tear (type 1), complete radial tear within 9 mm of the bony root attachment (type 2), bucket-handle tear with complete root detachment (type 3), complex oblique or longitudinal tear with complete root detachment (type 4), and bony avulsion fracture of the root attachment (type 5). Reprinted with permission from LaPrade et al. (2015b).

Table 1. Classification of anterior and posterior tears of the medial and lateral meniscal roots based on tear morphology

Type/Subtype	Description
1	Partial stable meniscal tear 0–9 mm from root attachment.
2	Complete radial meniscal tear to within 9 mm of bony root attachment.
2A	Complete radial meniscal tear 0–3 mm from root attachment.
2B	Complete radial tear 3–6 mm from root attachment.
2C	Complete radial tear 6–9 mm from root attachment.
3	Bucket-handle tear with complete meniscal root detachment.
4	Complex oblique meniscal tear extending into the root attachment.
5	Avulsion fracture of the meniscal root attachment.

root detachment (type 3), complex oblique or longitudinal tear with complete root detachment (type 4), and bony avulsion of the root attachment (type 5) (Figure 1 and Table 1) (LaPrade et al. 2015b). Type 2 is the most common type of tear. Forkel and Petersen (2012) described a classification system for lateral meniscus posterior horn lesions, whereby the lesions can be divided into 3 subcategories. Type 1 is avulsion of the root at the attachment on the tibial plateau with an intact meniscofemoral ligament. Type 2 is a radial tear of the posterior horn with an intact meniscofemoral ligament. Type 3 is a complete injury of the posterior horn of the lateral meniscus with rupture of the meniscofemoral ligament.

### Anatomy and mechanics

The most reproducible landmark for the medial meniscus root attachment described is an osseous landmark: the medial tibial eminence (MTE). The distance between the MTE and the center of the root attachment is 10 mm posterior and 0.7 mm lateral (Figure 2). Other consistent landmarks are the medial tibial plateau articular cartilage inflection point and the most proximal PCL tibial attachment, which is 4 mm lateral and 8 mm from the medial posterior root attachment center. Thus, the practical use during arthroscopic surgery would be to locate the medial tibial eminence and track posteriorly and laterally along the bony surface to identify the anatomic root attachment (Figure 2).

The most consistent landmark for the lateral meniscus posterior root attachment is the lateral tibial eminence (LTE). The center of the lateral meniscus posterior root is consistently found to be located 1.5 mm posterior and 4 mm medial to the LTE. The posterior root of the lateral meniscus attachment is located 4 mm medial to the lateral tibial plateau articular cartilage edge, and 13 mm to the most proximal edge of the PCL tibial attachment (Johannsen et al. 2012) (Figure 4).

The close relationship between the posterior meniscal roots and the PCL is important to identify, since failing to place the tunnel in its anatomical location can cause an iatrogenic injury to the tibial PCL attachment site (Johannsen et al. 2012) (Figures 3 and 4). In addition, it is important when reaming the PCL tibial tunnel to be aware of the posterior meniscal roots (LaPrade et al. 2015a).

The footprint area of the main central attachment fibers of the meniscus posterior roots is 30 mm<sup>2</sup> for the medial meniscus and 39 mm<sup>2</sup> for the lateral menisci (Johannsen et al. 2012).

The anteromedial root attachment is the strongest attachment (655 N) and the posterolateral is the weakest one (509 N) (Ellman et al. 2014). The increased mobility of the anterior roots may account for the higher failure strength when compared to the posterior roots (Benjamin et al. 1991).

Complete root tear avulsions significantly reduce the contact area and increase mean and peak contact pressures, because the circumferential fibers are not able to withstand the hoop stresses, emulating a complete meniscectomy (LaPrade et al. 2014a). Failure to reproduce the native attachments does not restore tibiofemoral contact pressure/area (LaPrade et al. 2015c). Repair of posteromedial meniscal root avulsions can restore the contact area to intact levels at all angles (Allaire et

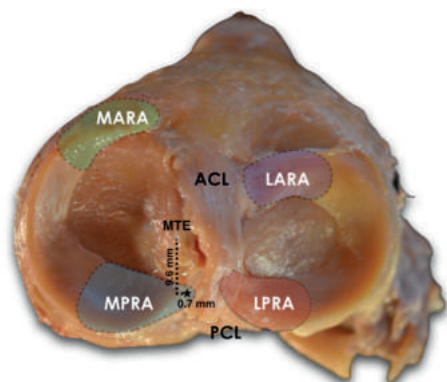


Figure 2. Cadaveric image (superior view) demonstrating the anatomical landmarks to identify a medial meniscus posterior root attachment (asterisk) in a right knee. MTE: medial tibial eminence; MARA: medial meniscus anterior root attachment; LARA: lateral meniscus anterior root attachment; MPRA: medial meniscus posterior root attachment; LPRA: lateral meniscus posterior root attachment.

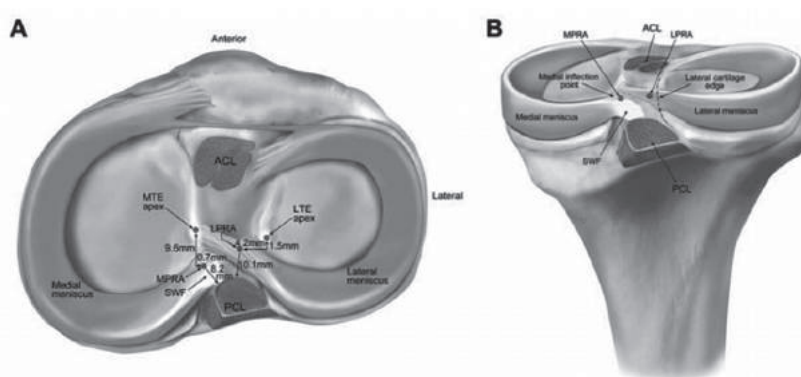


Figure 4. Pertinent anatomical relationships (right knee) as reported by Johannsen et al.7 A. Superior view. B. Posterior view. Reprinted with permission from Johannsen et al. (2012). ACL: anterior cruciate ligament bundle attachments; LPRA: lateral meniscus posterior root attachment; LTE: lateral tibial eminence; MPRA: medial meniscus posterior root attachment; MTE: medial tibial eminence; PCL: posterior cruciate ligament bundle attachments; SWF: shiny white fibers of posterior horn of medial meniscus.

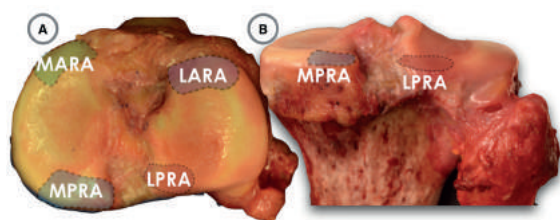


Figure 3. Right knee image demonstrating the close relationship between the posterior root attachments and the PCL.

al. 2008); however, repair of posterolateral meniscal root avulsion resulted in diminished contact areas that are substantially less than those of intact roots when pooled across all angles (LaPrade et al. 2014a).

**Evaluation**

Root tears are not always evident at physical examination or from magnetic resonance imaging (MRI), so all diagnostic measures should be used in order to effectively assess this pathology (De Smet and Mukherjee 2008). It is important to identify risk factors such as varus alignment and a high BMI, which can predispose to medial meniscus root tears; therefore, a thorough physical examination should be performed (Hwang et al. 2012). Presenting symptoms are posterior knee pain; an essential—but not always present—clinical diagnostic tool is the presence of a popping sound during light activities such as doing housework, going upstairs/downstairs, rising from a chair, and squatting (Lee et al. 2014). In clinical experience, a high-grade pivot shift and anterior drawer test in a patient with ACL injury may suggest a concomitant injury, and the meniscal roots should be thoroughly assessed during arthroscopy. These injuries have previously been overlooked, and they can

easily be missed if a thorough examination is not performed. The meniscal roots should be probed and the integrity of the the attachments evaluated during arthroscopy to avoid missing the diagnosis.

**Imaging**

MRI should be incorporated in the diagnostic workup of meniscal root tears to supplement patient history and physical examination findings. Previous studies have suggested that MRI is 93% sensitive, 100% specific, and has a positive predictive value of 100% for detection of meniscal root tears (De Smet and Mukherjee 2008, Choi et al. 2012). However, an accurate diagnosis of a root tear using MRI is highly dependent on the quality of the image and the skill of the radiologist (Ozkoc et al. 2008, Bhatia et al. 2014).

De Smet and Mukherjee (2008) recommended that suspected posterior meniscal root pathology should be evaluated at 3 locations on MRI: between the intercondylar tubercles, at the level of the lateral tubercle, and on the lateral edge of the tibial eminence adjacent to the lateral tubercle. In addition, the root tear should be evaluated in the coronal and sagittal planes, as visualization of both planar images yielded the highest sensitivity (De Smet and Mukherjee 2008). To increase diagnostic sensitivity and specificity further, T2-weighted sequences should be used to examine the tear (Lee et al. 2008) (Figure 5).

Medial meniscal extrusion, which is defined as a partial or total displacement of the meniscus from the tibial articular cartilage, is a finding highly correlated to the presence of a root tear (Costa et al. 2004). Medial meniscal extrusions greater than 3 mm are strongly associated with severe meniscal degeneration and meniscal root tears (Costa et al. 2004, Lerer et al. 2004). Another important sign is the ghost sign, which is the absence of an identifiable meniscus in the sagittal plane, or an increased signal replacing the normally dark

Downloaded by [50.183.158.184] at 20:40 28 June 2016

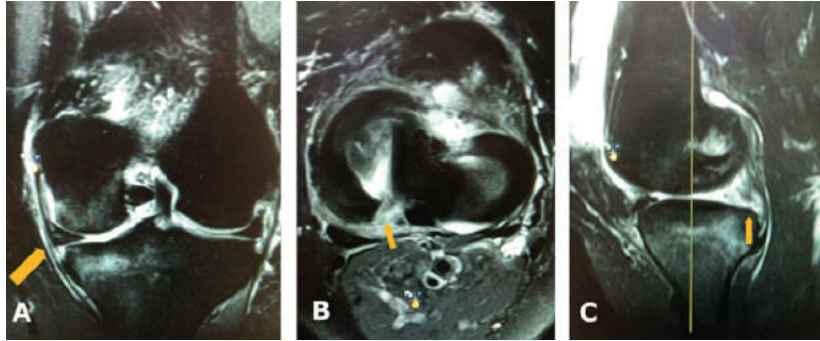


Figure 5. Visualization of meniscal root tears via magnetic resonance imaging. A. Coronal T2-weighted section demonstrating medial meniscal extrusion (arrow) (left knee). B. Axial image demonstrating high signal in region of meniscus root and posterior horn with a radial root tear (arrow) (right knee). C. Sagittal image demonstrating ghost sign (arrow) (right knee). Reprinted with permission from Bhatia et al. (2014).

meniscal tissue signal in more than 3 contiguous MRI cuts (Lerer et al. 2004, Papalia et al. 2013) (Figure 5).

### Treatment rationale

The treatment options for meniscal root tears include: non-operative treatment, meniscectomy, partial meniscectomy, and meniscal root repairs.

### Non-operative treatment

Non-operative treatment is an option for elderly patients, patients with significant comorbidities, and those with advanced osteoarthritis (Outerbridge grade-3 or -4 chondromalacia of the ipsilateral compartment). Symptomatic treatment with analgesics and an unloader brace can help to alleviate some of the symptoms.

### Meniscectomy

Meniscectomy has been used in the past, and can alleviate some of the symptoms (Ozkoc et al. 2008). Patients with knee osteoarthritis who do not respond to non-operative treatment and have symptoms such as pain and locking of the joint should be considered for meniscectomy. Patients with partial tears where the footprint is intact can have good outcome with a partial meniscectomy. It is still not clear how much of the footprint should be intact for the meniscus to maintain some function.

### Meniscal root repair

The main indications for meniscal repair are: (1) acute, traumatic root tears in patients with nearly normal or normal cartilage (Outerbridge 0–2); (2) chronic symptomatic root tears in young or middle-aged patients without significant pre-existing osteoarthritis (Bhatia et al. 2014). These injuries can develop subtly over time.

### Transosseous repair

Several authors have described transosseous repair tech-

niques, with each involving the passing of sutures through the meniscal root and tunnels in the proximal tibia. After passing through tibial tunnels, the sutures are then tied over a bone bridge or a post (Raustol et al. 2006, Kim et al. 2006, Ahn et al. 2007, Nicholas et al. 2009). Our preferred technique for fixation of posterior horn meniscal root tear involves 2 simple sutures in the meniscal root passed through 2 tunnels in the proximal tibia and tied over a cortical button (Figures 6 and 7).

The advantage of a button is that it is less invasive and has less risk of soft tissue irritation compared to screw and washer, as reported by Kim et al. (2006). This technique has been described in detail by Bhatia et al. (2014). It is important to fix the root at its anatomical attachment site and to resist displacement. An accurate positioning of the anchoring sites for the posterior horns is probably more important than the surgical technique itself (Packer and Rodeo 2009). Mechanical studies have found that a 3-mm non-anatomic displacement significantly alters meniscal function (Starke et al. 2010). The transtibial pullout technique facilitates anatomic reduction and fixation of the meniscal

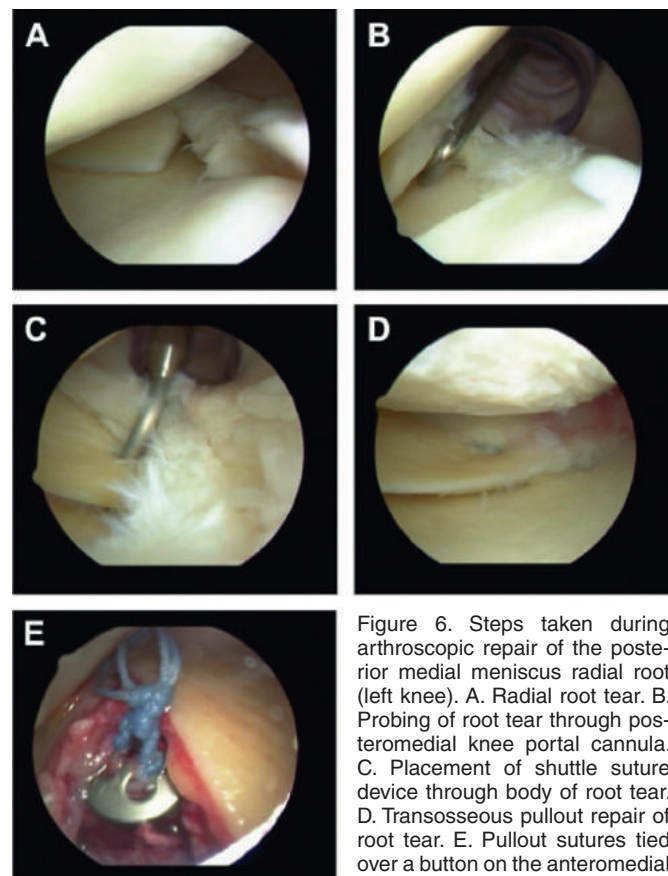


Figure 6. Steps taken during arthroscopic repair of the posterior medial meniscus radial root (left knee). A. Radial root tear. B. Probing of root tear through posteromedial knee portal cannula. C. Placement of shuttle suture device through body of root tear. D. Transosseous pullout repair of root tear. E. Pullout sutures tied over a button on the anteromedial tibia. Reprinted with permission from Bhatia et al. (2014).

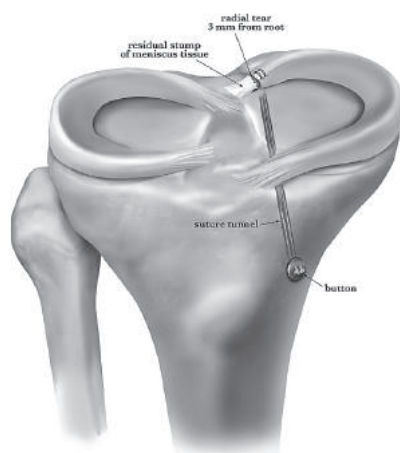


Figure 7. Preferred technique for fixation of a posterior horn medial meniscal root tear involves transosseous suture repair tied over a button on the anteromedial tibia. Proper tensioning and anatomical placement of the attachment are critical for healing and restoration of meniscal function. Reprinted with permission from Padalecki et al. (2014).

root. Padalecki et al. (2014) reported that an in situ pullout repair of radial tears restored the joint contact pressure and area similarly to the intact state. Drilling tibial tunnels may enhance healing due to the presence of growth factors and possibly bone marrow mesenchymal stem cells. The fixation construct has been reported to have significantly weaker fixation to the tibia than the native root (Kopf et al. 2011, Feucht et al. 2014). Feucht et al. (2014) reported a 2.2-mm displacement of the meniscal root repair with transtibial pullout under cyclic loading in a pig model, caused by the long length of the meniscus suture repair construct (bungee effect).

### Suture anchor repair

Suture anchor repair techniques for meniscal root tears involve an all-inside technique whereby 1 suture anchor with 2 sutures is secured in the cortical bone at the attachment site of the root to be repaired (Engelsohn et al. 2007, Kim et al. 2011b, Jung et al. 2012). A posteromedial portal may also be created to facilitate easier placement of the anchor at the native root attachment site. This portal should be placed higher than normal to achieve the right angle when placing the anchor, and to avoid collision with the medial femoral condyle. It is noteworthy that most of these studies were performed in individuals with concurrent grade-III sMCL injury, which greatly facilitates anchor placement in the medial compartment.

Proponents of this technique argue that it does not require tibial bone tunnels that could potentially interfere with concomitant ligament reconstruction tunnels. The risk of suture abrasion and tear, the bungee effect reported in transtibial technique, is also avoided. Displacement of the repair construct was observed under cyclic loading in a pig model, but it was less than in the transtibial technique (1.3 mm as opposed to 2.2 mm) (Feucht et al. 2014).

### Postoperative rehabilitation

After diagnosis and treatment of a meniscal root injury, rehabilitation is important for optimal patient outcome. Following a meniscal transtibial pullout root repair, patients should refrain from weight bearing for 6 weeks to protect the root repair and avoid hoop stress on the meniscus (Jones et al. 1996, Kim et al. 2011a, Papalia et al. 2013). When not working on physiotherapy, patients should wear a brace in full extension for 6 weeks. Physiotherapy postoperatively should be started early, to begin working on passive range-of-motion exercises 4 times a day. Patients who do not have access to physiotherapy should be instructed to take the brace off 4 times a day for passive ROM exercises. Knee flexion is limited to 0–90 degrees for the first 2 weeks, and then progresses to full knee motion as tolerated. Progressive advancement to full weight bearing begins at 6 weeks. Deep leg presses and squats greater than 70 degrees of knee flexion should be avoided for at least 4 months after surgery to protect the root repair. After 6 months of rehabilitation, full flexion, squatting, and return to full activities or sports is allowed (Lee et al. 2009, Kim et al. 2011a). Once running progression is complete, agility and cutting exercises may be initiated. The authors' rehabilitation protocol is summarized in Figure 8.

### Outcomes

Optimal treatment of meniscal root tears is still debatable, with conflicting clinical and radiologic results being reported. In a recent meta-analysis by Chung et al. (2016) on medial meniscal root tear repair, significant improvements in postoperative clinical subjective scores compared to preoperative status were reported, but the progression of arthrosis was not prevented and meniscal extrusion was not reduced. In a recent systematic review, Feucht et al. (2015e) reported improved outcomes of arthroscopic transtibial pullout repair for posterior medial meniscus root tears. Lysholm score improved from 52 preoperatively to 86 postoperatively, and 84% of the patients showed no progression of osteoarthritis by Kellgren-Lawrence grading. MRI showed no progression of cartilage degeneration in 82% of patients, and the medial meniscus extrusion was reduced in 56% of the patients. Based on second-look arthroscopy and MRI, the healing status was complete in 62% of cases, it was partial in 34%, and healing failed in 3% (Feucht et al. 2015e). In a retrospective study by Ozkoc et al. (2008) on patients with medial meniscus posterior root tear MMPRT treated with partial meniscectomy, Lysholm scores significantly improved but degenerative changes defined by Kellgren-Lawrence radiological grade had increased postoperatively at a mean follow-up time of 4.7 years. However, Chung et al. (2015) compared clinical and radiological outcomes between a medial meniscus root repair cohort and a partial meniscectomy cohort at a follow-up of at least 5 years, reporting significantly better Lysholm and International Knee Documentation Committee IKDC scores in the repair group than in the partial meniscectomy group.

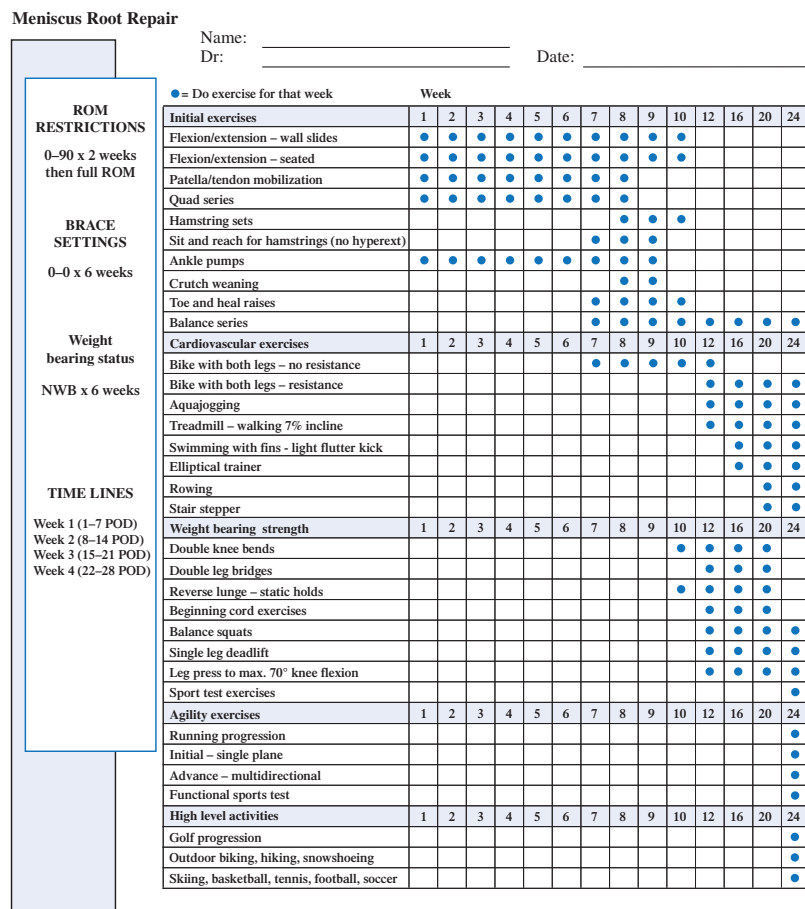


Figure 8. The authors' rehabilitation protocol after posterior meniscal root repair.

Both groups had a progression of Kellgren-Lawrence grade and medial joint space narrowing, but the repair group had less progression than partial meniscectomy group. The rate of conversion to total knee replacement was 35% in the partial meniscectomy group and zero in the repair group (Chung et al. 2015).

Outcomes of meniscal root repairs are still based on poorly designed studies in which the mean age of the patients is around 50 years (Lee et al. 2009, Kim et al. 2011a, 2011b, Moon et al. 2012, Jung et al. 2012). Most studies have found subjective improvement of the symptoms, but prevention of progression of arthrosis has not been adequately documented (Ozkoc et al. 2008, Feucht et al. 2015e, Chung et al. 2015, 2016). Poor reduction of the meniscus extrusion (Feucht et al. 2015e, Chung et al. 2016) and relatively low healing rates (Feucht et al. 2015e) have been reported. Failure to reduce meniscal extrusion, low reported healing rates, and the age of the patients may explain the poor radiographic results. Meniscal root repairs are technically challenging, and anatomic repair is paramount to the success of the surgery. This procedure might be better left to experienced surgeons with enough volume. There is still a need for more studies of better design to address some of the pending questions.

### Conclusions

Posterior meniscal root tears represent an often overlooked pathology. Surgical repair of the posterior meniscal root has improved patient-reported functional outcomes, although there are still conflicting reports on progression of cartilage degeneration. It is recommended that posterior meniscal root tears should be repaired in patients without advanced osteoarthritis (Outerbridge 3 and 4). Because of the importance of anatomic fixation of the meniscal roots, and the complexity of the procedure, it is best left to experienced hands.

Ahn J H, Wang J H, Yoo J C, Noh H K, Park J H. A pull out suture for transection of the posterior horn of the medial meniscus: using a posterior trans-septal portal. *Knee Surg Sports Traumatol Arthrosc* 2007; 15 (12): 1510-3.

Allaire R, Muriuki M, Gilbertson L, Harner C D. Biomechanical consequences of a tear of the posterior root of the medial meniscus. Similar to total meniscectomy. *J Bone Joint Surg Am* 2008; 90 (9): 1922-31.

Benjamin M, Evans E J, Rao R D, Findlay J A, Pemberton D J. Quantitative differences in the histology of the attachment zones of the meniscal horns in the knee joint of man. *J Anat* 1991; 177: 127-34.

Bhatia S, LaPrade C M, Ellman M B, LaPrade R F. Meniscal root tears: significance, diagnosis, and treatment. *Am J Sports Med* 2014; 42 (12): 3016-30.

Choi S H, Bae S, Ji S K, Chang M J. The MRI findings of meniscal root tear of the medial meniscus: emphasis on coronal, sagittal and axial images. *Knee Surg Sports Traumatol Arthrosc* 2012; 20 (10): 2098-103.

Chung K S, Ha J K, Yeom C H, Ra H J, Jang H S, Choi S H, Kim J G. Comparison of clinical and radiologic results between partial meniscectomy and refixation of medial meniscus posterior root tears: a minimum 5-year follow-up. *Arthroscopy* 2015; 31 (10): 1941-50.

Chung K S, Ha J K, Ra H J, Kim J G. A meta-analysis of clinical and radiographic outcomes of posterior horn medial meniscus root repairs. *Knee Surg Sports Traumatol Arthrosc* 2016; 24(5): 1455-68.

Costa C R, Morrison W B, Carrino J A. Medial meniscus extrusion on knee MRI: is extent associated with severity of degeneration or type of tear? *AJR Am J Roentgenol* 2004; 183 (1): 17-23.

De Smet A A, Mukherjee R. Clinical, MRI, and arthroscopic findings associated with failure to diagnose a lateral meniscal tear on knee MRI. *AJR Am J Roentgenol* 2008; 190 (1): 22-6.

Ellman M B, LaPrade C M, Smith S D, Rasmussen M T, Engebretsen L, Wijdicks C A, LaPrade R F. Structural Properties of the Meniscal Roots. *Am J Sports Med* 2014; 42 (8): 1881-7.

Ellman M B, James E W, LaPrade C M, LaPrade R F. Anterior meniscus root avulsion following intramedullary nailing for a tibial shaft fracture. *Knee Surg Sports Traumatol Arthrosc* 2015; 23 (4): 1188-91.

Engelsohn E, Umans H, Difelice G S. Marginal fractures of the medial tibial plateau: possible association with medial meniscal root tear. *Skeletal Radiol* 2007; 36 (1): 73-6.

Feucht M J, Grande E, Brunhuber J, Rosenstiel N, Burgkart R, Imhoff A B, Braun S. Biomechanical comparison between suture anchor and transtibial pull-out repair for posterior medial meniscus root tears. *Am J Sports Med* 2014; 42 (1): 187-93.

Feucht M J, Salzmann G M, Bode G, Pestka J M, Kuhle J, Sudkamp N P, Niemeyer P. Posterior root tears of the lateral meniscus. *Knee Surg Sports Traumatol Arthrosc* 2015a; 23 (1): 119-25.

Downloaded by [50.183.158.184] at 20:40 28 June 2016

- Feucht M J, Grande E, Brunhuber J, Rosenstiel N, Burgkart R, Imhoff A B, Braun S. Biomechanical evaluation of different suture materials for arthroscopic transtibial pull-out repair of posterior meniscus root tears. *Knee Surg Sports Traumatol Arthrosc* 2015b; 23 (1): 132-9.
- Feucht M J, Bigdon S, Mehl J, Bode G, Muller-Lantzsch C, Sudkamp N P, Niemeyer P. Risk factors for posterior lateral meniscus root tears in anterior cruciate ligament injuries. *Knee Surg Sports Traumatol Arthrosc* 2015c; 23 (1): 140-5.
- Feucht M J, Minzlaff P, Saier T, Lenich A, Imhoff A B, Hinterwimmer S. Avulsion of the anterior medial meniscus root: case report and surgical technique. *Knee Surg Sports Traumatol Arthrosc* 2015d; 23 (1): 146-51.
- Feucht M J, Kuhle J, Bode G, Mehl J, Schmal H, Sudkamp N P, Niemeyer P. Arthroscopic Transtibial Pullout Repair for Posterior Medial Meniscus Root Tears: A Systematic Review of Clinical, Radiographic, and Second-Look Arthroscopic Results. *Arthroscopy* 2015e; 31 (9): 1808-16.
- Forkel P, Petersen W. Posterior root tear fixation of the lateral meniscus combined with arthroscopic ACL double bundle reconstruction: technical note of transosseous fixation using the tibial PL tunnel. *Arch Orthop Trauma Surg* 2012; 132 (3): 387-91.
- Han S B, Shetty G M, Lee D H, Chae D J, Seo S S, Wang K H, Yoo S H, Nha K W. Unfavorable results of partial meniscectomy for complete posterior medial meniscus root tear with early osteoarthritis: a 5- to 8-year follow-up study. *Arthroscopy* 2010; 26 (10): 1326-32.
- Hwang B Y, Kim S J, Lee S W, Lee H E, Lee C K, Hunter D J and K. A. Jung K A. Risk factors for medial meniscus posterior root tear. *Am J Sports Med* 2012; 40 (7): 1606-10.
- Johannsen A M, Civitarese D M, Padalecki J R, Goldsmith M T, Wijdicks C A, R. F. LaPrade R F. Qualitative and quantitative anatomic analysis of the posterior root attachments of the medial and lateral menisci. *Am J Sports Med* 2012; 40 (10): 2342-7.
- Jones R S, Keene G C, Learmonth D J, Bickerstaff D, Nawana N S, Costi J J, Pearcy M J. Direct measurement of hoop strains in the intact and torn human medial meniscus. *Clin Biomech (Bristol, Avon)* 1996; 11 (5): 295-300.
- Jung Y H, Choi N H, Oh J S, Victoroff B N. All-inside repair for a root tear of the medial meniscus using a suture anchor. *Am J Sports Med* 2012; 40 (6): 1406-11.
- Kim Y M, Rhee K J, Lee J K, Hwang D S, Yang J Y, Kim S J. Arthroscopic pullout repair of a complete radial tear of the tibial attachment site of the medial meniscus posterior horn. *Arthroscopy* 2006; 22 (7): 795.e1-4.
- Kim Y J, Kim J G, Chang S H, Shim J C, Kim S B, Lee M Y. Posterior root tear of the medial meniscus in multiple knee ligament injuries. *Knee* 2010; 17 (5): 324-8.
- Kim S B, Ha J K, Lee S W, Kim D W, Shim J C, Kim J G, Lee M Y. Medial meniscus root tear refixation: comparison of clinical, radiologic, and arthroscopic findings with medial meniscectomy. *Arthroscopy* 2011a; 27 (3): 346-54.
- Kim J H, Chung J H, Lee D H, Lee Y S, Kim J R, Ryu K J. Arthroscopic suture anchor repair versus pullout suture repair in posterior root tear of the medial meniscus: a prospective comparison study. *Arthroscopy* 2011b; 27 (12): 1644-53.
- Kopf S, Colvin A C, Muriuki M, Zhang X, Harner C D. Meniscal root suturing techniques: implications for root fixation. *Am J Sports Med* 2011; 39 (10): 2141-6.
- LaPrade C M, Jansson K S, Dornan G, Smith S D, Wijdicks C A, LaPrade R F. Altered tibiofemoral contact mechanics due to lateral meniscus posterior horn root avulsions and radial tears can be restored with in situ pull-out suture repairs. *J Bone Joint Surg Am* 2014a; 96 (6): 471-9.
- LaPrade C M, James E W, Engebretsen L, LaPrade R F. Anterior medial meniscal root avulsions due to malposition of the tibial tunnel during anterior cruciate ligament reconstruction: two case reports. *Knee Surg Sports Traumatol Arthrosc* 2014b; 22 (5): 1119-23.
- LaPrade C M, Smith S D, Rasmussen M T, Hamming M G, Wijdicks C A, Engebretsen L, Feagin J A, LaPrade R F. Consequences of tibial tunnel reaming on the meniscal roots during cruciate ligament reconstruction in a cadaveric model, Part 2: The posterior cruciate ligament. *Am J Sports Med* 2015a; 43 (1): 207-12.
- LaPrade C M, James E W, Cram T R, Feagin J A, Engebretsen L, LaPrade R F. Meniscal root tears: a classification system based on tear morphology. *Am J Sports Med* 2015b; 43 (2): 363-9.
- LaPrade C M, Foad A, Smith S D, Turnbull T L, Dornan G J, Engebretsen L, Wijdicks C A, LaPrade R F. Biomechanical consequences of a nonanatomic posterior medial meniscal root repair. *Am J Sports Med* 2015c; 43 (4): 912-20.
- LaPrade C M, Jisa K A, Cram T R, LaPrade R F. Posterior lateral meniscal root tear due to a malpositioned double-bundle anterior cruciate ligament reconstruction tibial tunnel. *Knee Surg Sports Traumatol Arthrosc* 2015d; 23 (12): 3670-3.
- Lee S Y, Jee W H, Kim J M. Radial tear of the medial meniscal root: reliability and accuracy of MRI for diagnosis. *AJR Am J Roentgenol* 2008; 191 (1): 81-5.
- Lee J H, Lim Y J, Kim K B, Kim K H, Song J H. Arthroscopic pullout suture repair of posterior root tear of the medial meniscus: radiographic and clinical results with a 2-year follow-up. *Arthroscopy* 2009; 25 (9): 951-8.
- Lee D W, Ha J K, Kim J G. Medial meniscus posterior root tear: a comprehensive review. *Knee Surg Relat Res* 2014; 26 (3): 125-34.
- Lerer D B, Umans H R, Hu M X, Jones M H. The role of meniscal root pathology and radial meniscal tear in medial meniscal extrusion. *Skeletal Radiol* 2004; 33 (10): 569-74.
- Marzo J M, Gurske-DePerio J. Effects of medial meniscus posterior horn avulsion and repair on tibiofemoral contact area and peak contact pressure with clinical implications. *Am J Sports Med* 2009; 37 (1): 124-9.
- Matheny L M, Ockuly A C, Steadman J R, LaPrade R F. Posterior meniscus root tears: associated pathologies to assist as diagnostic tools. *Knee Surg Sports Traumatol Arthrosc* 2015; 23 (10): 3127-31.
- Moon H K, Koh Y G, Kim Y C, Park Y S, Jo S B, Kwon S K. Prognostic factors of arthroscopic pull-out repair for a posterior root tear of the medial meniscus. *Am J Sports Med* 2012; 40 (5): 1138-43.
- Nicholas S J, Golant A, Schachter A K, Lee S J. A new surgical technique for arthroscopic repair of the meniscus root tear. *Knee Surg Sports Traumatol Arthrosc* 2009; 17 (12): 1433-6.
- Ozkoc G, Circi E, Gonc U, Irgit K, Pourbagher A, Tandogan R N. Radial tears in the root of the posterior horn of the medial meniscus. *Knee Surg Sports Traumatol Arthrosc* 2008; 16 (9): 849-54.
- Packer J D, Rodeo S A. Meniscal allograft transplantation. *Clin Sports Med* 2009; 28 (2): 259-83.
- Padalecki J R, Jansson K S, Smith S D, Dornan G J, Pierce C M, Wijdicks C A, LaPrade R F. Biomechanical consequences of a complete radial tear adjacent to the medial meniscus posterior root attachment site: in situ pull-out repair restores derangement of joint mechanics. *Am J Sports Med* 2014; 42 (3): 699-707.
- Papalia R, Vasta S, Franceschi F, D'Adamo S, Maffulli N, Denaro V. Meniscal root tears: from basic science to ultimate surgery. *Br Med Bull* 2013; 106: 91-115.
- Ra H J, Ha J K, Jang H S, Kim J G. Traumatic posterior root tear of the medial meniscus in patients with severe medial instability of the knee. *Knee Surg Sports Traumatol Arthrosc* 2015; 23 (10): 3121-6.
- Raustol O A, Poelstra K A, Chhabra A, Diduch D R. The meniscal ossicle revisited: etiology and an arthroscopic technique for treatment. *Arthroscopy* 2006; 22 (6): 687.e1-3.
- Schillhammer C K, Werner F W, Scuderi M G, Cannizzaro J P. Repair of lateral meniscus posterior horn detachment lesions: a biomechanical evaluation. *Am J Sports Med* 2012; 40 (11): 2604-9.
- Starke C, Kopf S, Grobel K H, Becker R. The effect of a nonanatomic repair of the meniscal horn attachment on meniscal tension: a biomechanical study. *Arthroscopy* 2010; 26 (3): 358-65.
- Watson J N, Wilson K J, LaPrade C M, Kennedy N I, Campbell K J, Hutchinson M R, Wijdicks C A, LaPrade R F. Iatrogenic injury of the anterior meniscal root attachments following anterior cruciate ligament reconstruction tunnel reaming. *Knee Surg Sports Traumatol Arthrosc* 2015; 23 (8): 2360-6.