







The Complex Knee Webinar  
What would you do with this case?

April 30<sup>th</sup>  
1pm CST **LIVE STREAMING**

Robert LaPrade  Lars Engbrechtsen  Tim Spalding 

Hosted by  @jorge\_chahla  @jachahla



**CASE N°2**

Robert LaPrade 



**LIVE STREAMING**

**CLINICAL PRESENTATION**


17 y/o male

Trampoline Accident - May 2009

Rt Knee Anterior KD  
Emergent Popl Art Bypass Graft

Ex Fix for 2 months- Unrecognized Prox Tibial Fx


Unable to participate in higher level activity



**LIVE STREAMING**

**PHYSICAL EXAM**

- ✓ Antalgic Gait
- ✓ Significant instability
- ✓ Heel Height R 14 vs 3cm
- ✓ Posterior Drawer 3+
- ✓ No Varus, Increased Valgus
- ✓ Positive Dial Test at 30 and 90°



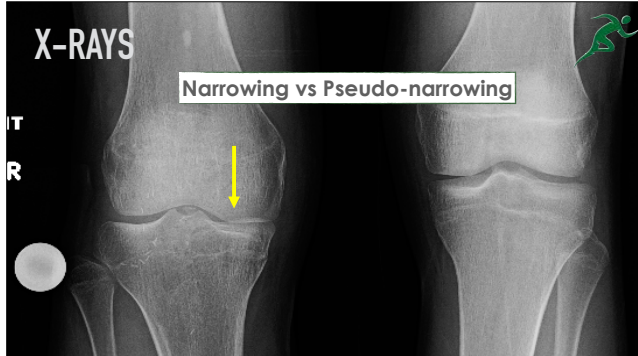
**LIVE STREAMING**

**WHAT SHOULD WE ASK FOR?**



**X-RAYS**

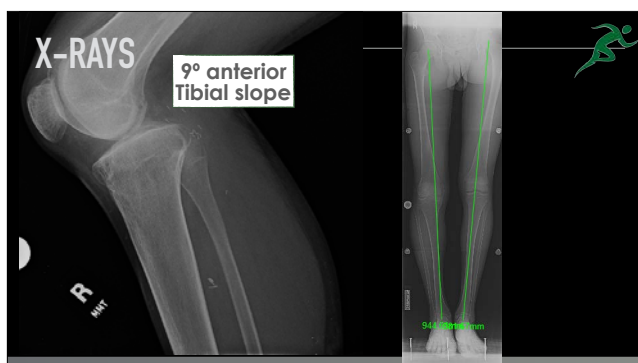
Narrowing vs Pseudo-narrowing



**LIVE STREAMING**

**X-RAYS**

9° anterior Tibial slope



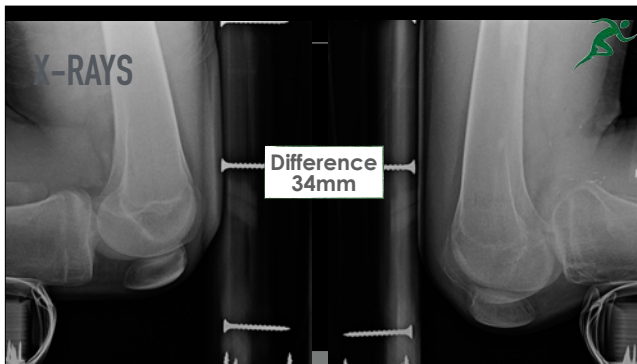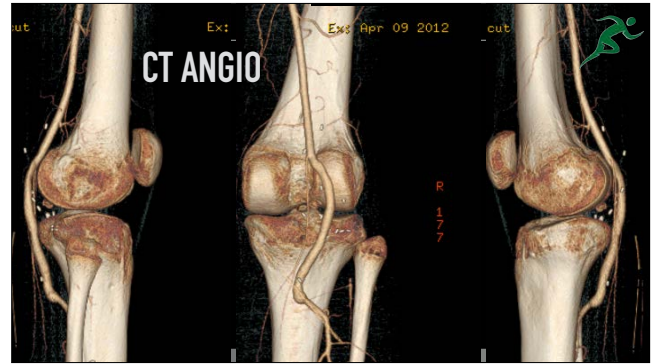
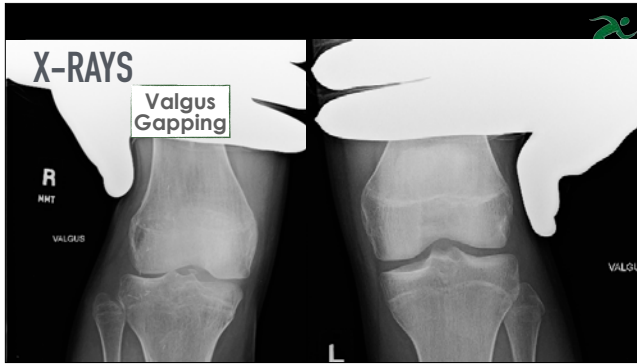
**LIVE STREAMING**

**X-RAYS**

9° anterior Tibial slope



**LIVE STREAMING**



## IMAGING

- ✓ Alignment - Moderate Genu Varus
- ✓ Malunion anteromedial tibial plateau fx  
Sagittal tibial slope = 9° anterior slope - 18° diff CL side
- ✓ Varus stress xrays - NO Gapping
- ✓ Valgus stress xrays - Inconclusive
- ✓ PCL stress xrays - 34mm



## WHAT TO DO?

- ✓ Significant Recurvatum
- ✓ Varus Malalignment
- ✓ Anterior Tibial Slope
- ✓ PCL G III Tear - ACL Status unclear
- ✓ Collateral Ligaments - MCL Status Unclear




## STRATEGY

- ✓ What do we tell the patient? Expectations?
- ✓ Single Stage vs Staged
- ✓ If 2 stages... how much time apart?
- ✓ What order?
- ✓ Other considerations?

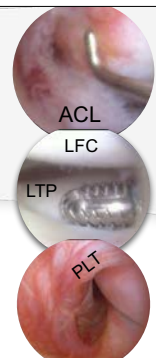


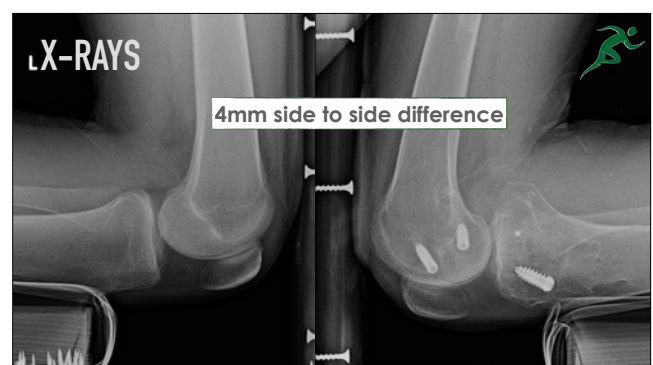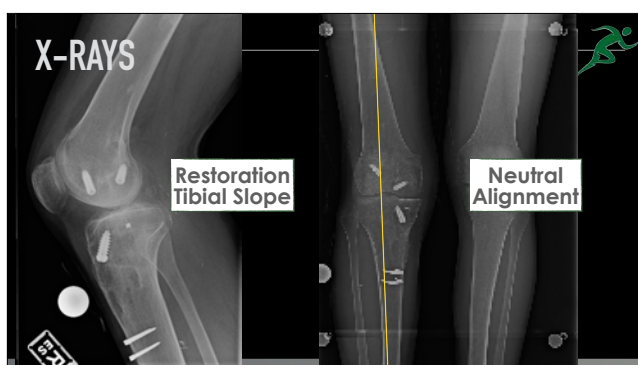
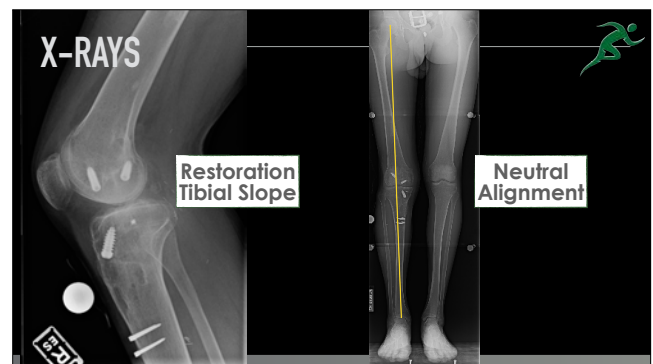
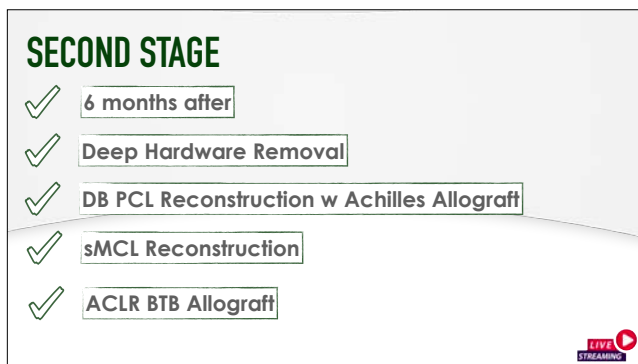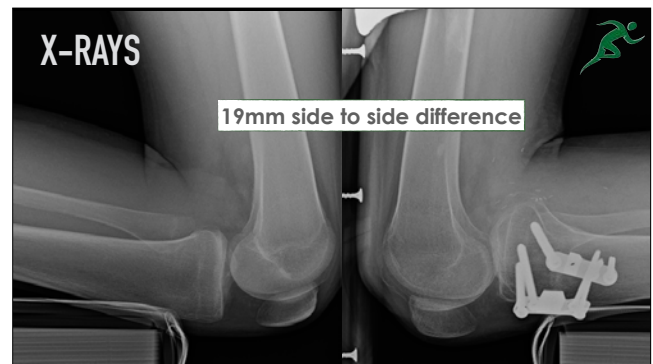
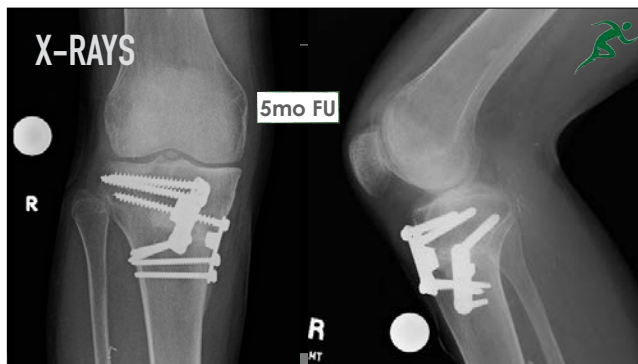
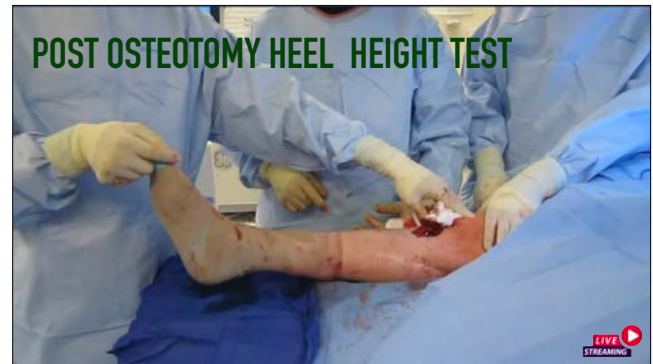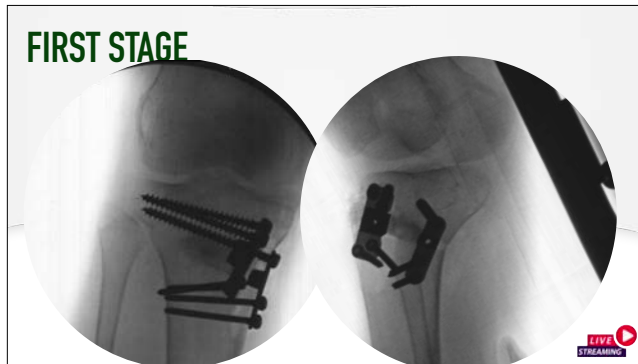
## PHYSICAL EXAM



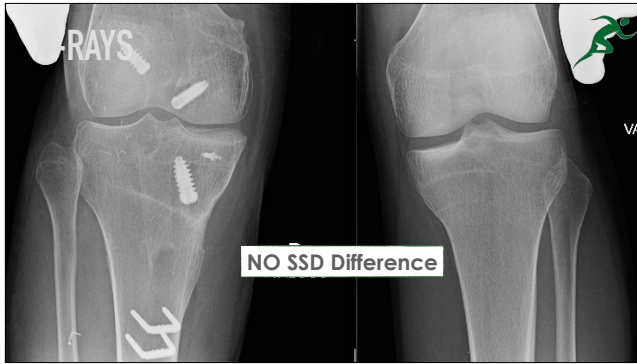
## FIRST STAGE

- ✓ Medial Gapping
- ✓ ACL Attenuated
- ✓ No Drive Through Sign PLC
- ✓ Popliteus Intact



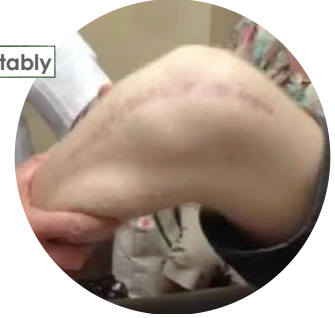





## 9MO FOLLOW UP

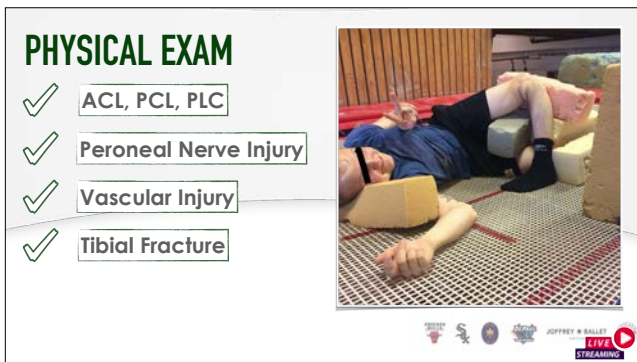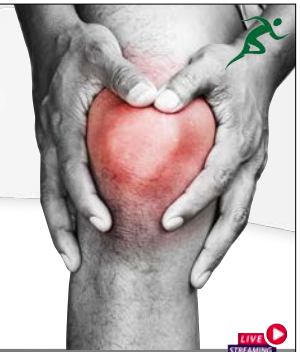
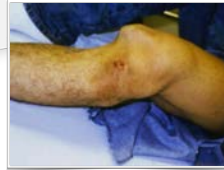- ✓ Able to walk comfortably
- ✓ Mild Instability
- Quad still weak
- ✓ What do you do



## CLINICAL PRESENTATION

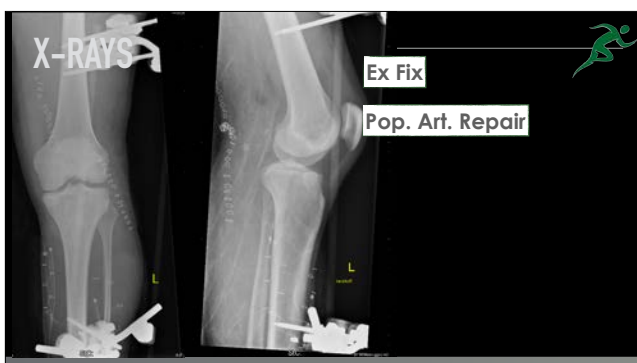
20 y/o male

Trampoline Injury



## STRATEGY

- ✓ What do we tell the patient? Expectations?
- ✓ Single Stage vs Staged
- ✓ If 2 stages... how much time apart?
- ✓ Ex Fix? Considerations for vascular repair?
- ✓ Other considerations?



## STRATEGY

- ✓ Ex Fix - How much time?
- ✓ Ex Fix Removal - Scope or no scope?
- ✓ Motion Goals?
- ✓ Second Stage?

