

## Technical Note

# Endoscopic Trochanteric Bursectomy and Iliotibial Band Release for Persistent Trochanteric Bursitis

Justin J. Mitchell, M.D., Jorge Chahla, M.D., Alexander R. Vap, M.D.,  
Travis J. Menge, M.D., Eduardo Soares, M.D., Jonathan M. Frank, M.D.,  
Chase S. Dean, M.D., and Marc J. Philippon, M.D.

**Abstract:** Lateral hip pain associated with trochanteric bursitis is a common orthopedic condition, and can be debilitating in chronic or recalcitrant situations. Conservative management is the most common initial treatment and often results in resolution of symptoms and improved patient outcomes. These modalities include rest, activity modification, physical therapy, anti-inflammatory medication, or corticosteroid injections. However, there is a subset of patients in which symptoms persist despite exhaustive conservative modalities. For these patients, trochanteric bursectomy is a surgical option to address persistent pathology. Previous literature indicates that both open and arthroscopic surgical techniques can be used to address the inflamed bursa and results in good patient outcomes. However, recent advances in hip arthroscopy have allowed for improvements in minimally invasive techniques to address intracapsular and extracapsular pathology of the hip, including recalcitrant trochanteric bursitis. The purpose of this manuscript is to describe our technique for a minimally invasive arthroscopic trochanteric bursectomy.

**T**rochanteric bursitis is a common condition that can result in significant hip and buttock pain. It has been well described in the prior literature, dating back to Stegemann's initial description in 1923.<sup>1</sup> Patients commonly present with complaints of lateral-sided hip or buttock pain, often without an inciting event or traumatic injury. Repetitive microtrauma due to friction between the greater trochanter and iliotibial band (ITB) during hip motion can result in inflammation of the interposed bursa.<sup>2</sup>

Although a majority of patients can be successfully treated with conservative management, including rest, activity modification, physical therapy, anti-inflammatory medication, or corticosteroid injections, there remains a subset of patients who experience persistent symptoms.<sup>3,4</sup> A number of open surgical techniques to address both the inflamed bursa and the ITB have been reported with good outcomes. Slawski and Howard<sup>5</sup> described an open release of the ITB with excision of the trochanteric bursa in 5 patients. All patients returned to unrestricted activity, and the average Harris Hip score improved from 51.7 preoperatively to 95.0 after surgery.

More recently, however, there has been increased interest in the advantages of a minimally invasive approach for the surgical treatment of recalcitrant trochanteric bursitis through the use of endoscopic techniques. The knowledge of trochanteric bursitis and associated surgical techniques to address this pathology continue to evolve. The purpose of this technical note was to describe our technique for a minimally invasive arthroscopic trochanteric bursectomy.

*From The Steadman Clinic (J.J.M., A.R.V., T.J.M., E.S., J.M.F., M.J.P.) and the Steadman Philippon Research Institute (J.J.M., J.C., A.R.V., T.J.M., E.S., J.M.F., C.S.D., M.J.P.), Vail, Colorado, U.S.A.*

*The authors report the following potential conflict of interest or source of funding: M.J.P. receives institutional support from Arthrex, Ossur, Siemens, and Smith & Nephew; board membership fees from Vail Valley Surgery Center, Steadman Philippon Research Institute, Vail Health Services, ISHA, and ASIAM; consultancy fees from Smith & Nephew, ConMed Linvatec, Bledsoe, Slack, Elsevier, and Donjoy; grants from Smith & Nephew, ArthroSurface, HIPCO, MIS, Ossur, Arthrex, and Siemens; and royalties from Smith & Nephew, ConMed Linvatec, Bledsoe, Slack, Elsevier, and Donjoy.*

*Received May 24, 2016; accepted July 11, 2016.*

*Address correspondence to Marc J. Philippon, M.D., Steadman Philippon Research Institute, The Steadman Clinic, 181 West Meadow Drive, Suite 400, Vail, CO 81657, U.S.A. E-mail: [mjp@sprivail.org](mailto:mjp@sprivail.org)*

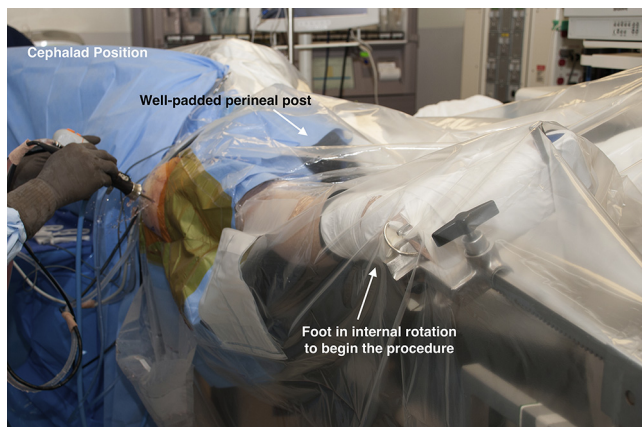
*© 2016 by the Arthroscopy Association of North America  
2212-6287/16462/\$36.00*

*<http://dx.doi.org/10.1016/j.eats.2016.07.005>*

## Surgical Technique

### Operative Indications

Trochanteric bursitis often affects middle-aged patients, females with wide pelves, patients with prominent



**Fig 1.** Intraoperative photograph of a patient positioned for a right hip arthroscopy. The foot is initially placed in internal rotation with a well-padded perineal post between the legs.

greater trochanters, or athletes who perform adduction across the midline (such as runners).<sup>6</sup> This can lead to lateral hip or buttock pain and cause difficulty with activity, decreased function, or an inability to lie on the affected side. The pain may increase in intensity with adduction and internal rotation due to compression of the overlying ITB against the bursa.<sup>6,7</sup> First-line treatment involves nonsurgical modalities including physical therapy, activity modification, oral anti-inflammatories, iontophoresis, or corticosteroid injections. However, in patients with chronic recalcitrant trochanteric bursitis that does not respond to nonsurgical interventions, endoscopic bursectomy is an effective and viable alternative to open bursectomy.<sup>7</sup>

### Patient Positioning and Anesthesia

In the operating room, a combined spinal-epidural is performed for analgesia and relaxation. The patient is placed supine on a traction table (Steris/Amsco, Mentor, OH) with all bony prominences well padded. An extrawide perineal post is placed to minimize pressure on the pudendal nerve and force the femoral head laterally to help distract the joint. The arm on the operative side is crossed over the chest. The patients' feet are wrapped in cotton padding and placed securely into traction boots.

### Diagnostic Arthroscopy

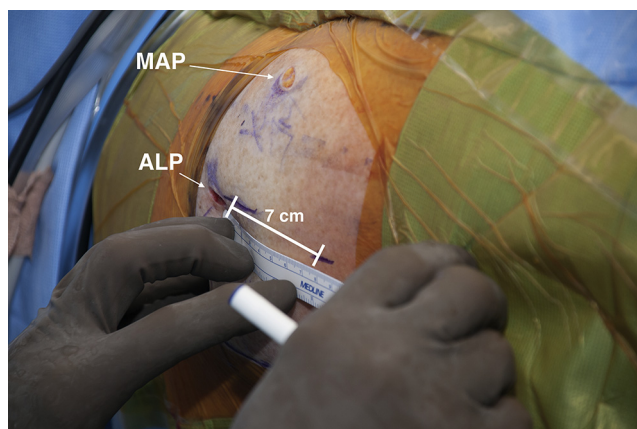
Endoscopic trochanteric bursectomy can be performed in isolation, or in combination with other arthroscopic hip procedures when concomitant intra- or extra-articular pathologies are present (Video 1). When performed in conjunction with other procedures, the intra-articular portion of the arthroscopic procedure is performed first with the patient in the supine position. After routine preparation and draping of the affected hip, standard anterolateral and midanterior portals are established (Fig 1). The placement of the

anterolateral portal is of utmost importance, as it is later used for completion of the arthroscopic trochanteric bursectomy. The anterolateral portal is placed just anterior and distal to the tip of the greater trochanter to allow access to the central compartment, and a diagnostic arthroscopy is performed using a 70° arthroscope (Smith & Nephew, Andover, MA) to evaluate for intra-articular pathology. All indicated procedures are then performed based on preoperative diagnoses and intraoperative findings, including treatment of labral tears, femoroacetabular impingement, chondral damage, and any other pathology.

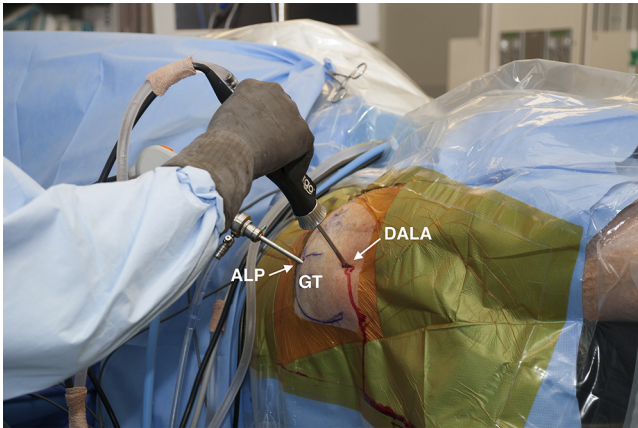### Trochanteric Bursectomy and Iliotibial Band Release

After completion of all intra-articular procedures, attention is directed laterally to the region overlying the previously marked greater trochanter. A third arthroscopic distal anterolateral accessory portal is created 7 cm distal to the standard anterolateral portal (Fig 2). The arthroscope is placed into the anterolateral portal and moved into the peritrochanteric space adjacent and superficial to the ITB. An arthroscopic shaver (Smith & Nephew) is inserted into the same space through the previously created distal anterolateral accessory portal, and the fascia and soft tissues overlying the iliotibial band are debrided with the mechanical shaver (Fig 3). This debridement allows for direct visualization and identification of the posterior aspect of the ITB, which allows for identification and protection of any perforating vessels.

With the ITB fully visualized, the mechanical shaver is removed, and a Beaver Blade (Smith & Nephew) is placed through the distal anterolateral portal. The blade is used to perform a release of the IT band at the mid-portion of the tendon. Incising the ITB 2 cm in a longitudinal direction, and 2 cm in a horizontal direction, a



**Fig 2.** Intraoperative photograph of a right hip. A standard anterolateral portal (ALP) and midanterior portal (MAP) have been established. For the procedure, a distal anterolateral accessory portal is established 7 cm distal to the ALP.



**Fig 3.** The right hip during arthroscopic trochanteric bursectomy. The arthroscope is placed in the anterolateral portal (ALP) and the arthroscopic shaver is placed in the distal anterolateral accessory (DALA) portal to perform the procedure. (GT, greater trochanter.)

cruciate ITB release is created (Fig 4). The horizontal limb of the release is perpendicular to both the long axis of the ITB and the previously made longitudinal release incision. The edges of the released tissue are then debrided with the mechanical shaver to expand the decompressed area and to allow for placement of the arthroscopic camera, mechanical shaver, and radio-frequency devices to access the underlying greater trochanteric bursa.

An extensive greater trochanteric bursectomy is then performed with the mechanical shaver placed through the distal anterolateral accessory portal and ITB release, exposing the greater trochanter and the gluteus medius (Fig 5). The foot may be rotated from a neutral position to an internally rotated position to fully visualize the bursal space. A flexible radiofrequency probe (Dyonics Efflex; Smith & Nephew) is used to ensure hemostasis throughout the procedure, and care is taken to avoid

extensively debriding posterior tissues, as this can place the sciatic nerve at risk for injury, especially when the foot is internally rotated. Further, care is taken to preserve the hip joint capsule and the external rotator muscle tendons, and arthroscopic instruments are used under foot-pedal control to allow for rapid cessation of instrument function and to allow for increased care and precision.

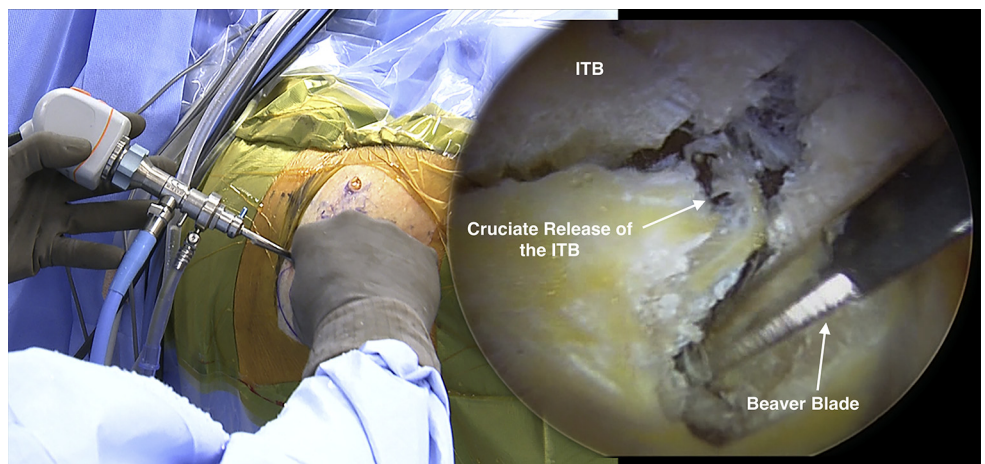
### Dynamic Evaluation and Closure

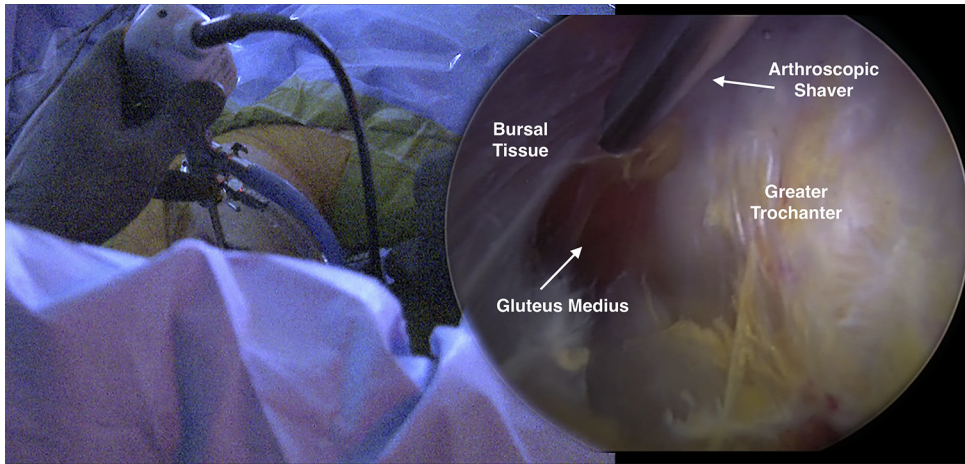
After completion of the bursectomy, the hip is dynamically assessed to ensure that there is no catching or areas of residual impingement on the trochanter. The arthroscopic instruments are then removed from the portals and the arthroscopic portals are closed using interrupted nylon suture.

### Postoperative Rehabilitation

After an arthroscopic trochanteric bursectomy, patients are allowed progressive weight bearing as tolerated with gentle active and passive range of motion for 2 weeks, followed by progression to full activity by 4 to 6 weeks. However, rehabilitation is modified for those who undergo concomitant intra-articular procedures such as labral repair and femoral osteoplasty. In the latter cases, patients are allowed 20 lb (~9 kg) of flat-foot weight bearing for 21 days, followed by 1 week of weaning off of crutches. A continuous passive motion machine is used for 4 weeks for 6 to 8 hours per day. This period of time increases to 8 hours per day for 8 weeks if microfracture is performed. An antirotation bolster to prevent hip external rotation is used for 21 days after surgery. A hip brace is placed to restrict extension and external rotation for 21 days postoperatively. Physical therapy aimed at first restoring passive motion is started on postoperative day 1, followed by active motion and lastly strength. Passive hip circumduction motions to prevent adhesions are also

**Fig 4.** Intraoperative image of a right hip (left) and arthroscopic image of the same hip (right) showing a cruciate release performed in the iliotibial band (ITB) to reveal the underlying bursa. The arthroscope is placed through the anterolateral portal and a Beaver Blade is held in the surgeon's right hand and placed through the distal anterolateral accessory portal.





**Fig 5.** Intraoperative image of a right hip (left) and arthroscopic image of the same hip (right) showing an arthroscopic bursectomy revealing the underlying greater trochanter and gluteus medius muscle and tendon. The arthroscope is placed through the anterolateral portal and an arthroscopic shaver is held in the surgeon's right hand and placed through the distal anterolateral accessory portal.

performed 4 times daily. Endurance strengthening is commenced after motion is maximized and good stability in gait and movement is observed.

### Discussion

Trochanteric bursitis is a common entity and can be caused by impaired vascularity, overlying ITB impingement, soft-tissue calcifications, or muscular spasm secondary to lumbar disorders.<sup>8</sup> Although many patients respond to conservative treatment modalities, recalcitrant bursitis can lead to chronic and disabling hip pain in a subset of cases.

Despite the frequency in which it is encountered, arriving at the correct diagnosis can be challenging given the complex anatomic relationships surrounding the hip. Greater trochanteric pain syndrome is the name under which a wide spectrum of etiologies can present with similar symptomatology and encompasses pain in any of the 5 muscle tendons that insert on the greater trochanter, or the 3 bursae in this region.<sup>9</sup> Pain in the areas surrounding these structures can mimic greater trochanteric bursitis, and the importance of a dedicated and complete physical examination is paramount to avoid misdiagnosis.<sup>10</sup>

The most common and effective method for diagnosing greater trochanteric bursitis is deep palpation of the greater trochanter by placing deep lateral pressure directly over the bony prominence of the

proximal femur. The patient is placed in a lateral decubitus position, with the affected hip adducted and facing away from the examination table. The test is considered positive when the patient notes reproduction of pain with this deep palpation.<sup>11</sup> Although a thorough clinical examination is typically sufficient to determine the cause of the pain, bedside ultrasonography or magnetic resonance imaging can be helpful in revealing pathology when the diagnosis is uncertain.<sup>12</sup>

Although most patients respond to nonsurgical management, surgical intervention may be required for recalcitrant cases or in cases that have failed conservative management. In this regard, good results have been reported for both open and arthroscopic procedures.<sup>8,9</sup> Fox<sup>8</sup> reported on 27 patients with minimum 1-year follow-up who underwent an arthroscopic procedure, and documented that only 1 patient (3.7%) experienced recurrent symptoms and was unsatisfied with the outcome. Baker and colleagues<sup>7</sup> similarly found significant improvements in outcome scores in 30 patients who underwent arthroscopic bursectomy at a mean of 26.1 months after surgery. A systematic review by Del Buono et al.<sup>13</sup> suggested that in the management of greater trochanteric pain syndrome, corticosteroid injection has a marked short-term benefit that is rapidly reversed after a few months, with high rates of recurrence. They also concluded that despite the good results

**Table 1.** Pearls and Pitfalls

| Pearls   | Pitfalls  |
|--|---|
| To avoid difficulty with portal creation and entry, intra-articular procedures should be completed before the trochanteric bursectomy. | Extravasation of fluid into the extracapsular soft tissues can make intra-articular portal passage difficult if trochanteric bursectomy is performed prior to other procedures. |
| Care should be taken to expose the iliotibial band in its entirety to ensure appropriate placement of the release.                     | Extensive posterior debridement, especially with the foot in internal rotation, can place the sciatic nerve at risk.  |
| Radiofrequency ablation devices can be used to ensure appropriate hemostasis throughout the procedure.                                 | Reckless debridement of the hypertrophic bursa can lead to damage or disruption of the tendons of the short external rotators of the hip.                                       |

**Table 2.** Advantages and Disadvantages

| Advantages  | Disadvantages   |
|---|---|
| This technique allows for complete visualization of the trochanteric bursal space.  | Arthroscopic bursectomy can be technically challenging and should be performed by skilled arthroscopists.   |
| Arthroscopic bursectomy limits soft tissue dissection and minimizes incisions and blood loss normally created by open techniques. | The cruciate release of the iliotibial band yields limited entry for arthroscopic instruments, necessitating careful technique for entry and procedural work within the bursal space. |

reported after surgical procedures, all the studies are retrospective case series that have a relatively small sample and highly heterogeneous reporting success rates difficult to compare and interpret.

In this technical note, we present our preferred method for treatment of trochanteric bursitis with a minimally invasive endoscopic procedure. There are several technical pearls and pitfalls associated with this procedure (Table 1) as well as advantages and disadvantages (Table 2). Although technically demanding, limited soft tissue disruption and diminished blood loss compared with open procedures are advantages for this technique. Long-term studies should be performed to ensure maintenance of good outcomes with time when performing this technique. This technique will continue to be studied and evaluated within our group, and we also encourage other surgeons to further evaluate the validity of this technique and to perform continued assessment for long-term results.

## References

1. Stegemann H. Die chirurgische bedeutung paraartikularer kalkablagerungen. *Arch Klin Chir* 1923;125:718-738.
2. Clancy WG. Runner's injuries. Part two. Evaluation and treatment of specific injuries. *Am J Sports Med* 1980;8:287-289.
3. Schapira D, Nahir M, Scharf Y. Trochanteric bursitis: A common clinical problem. *Arch Phys Med Rehabil* 1986;67:815-817.
4. Shbeeb MI, Duffy JD, Michet CJ Jr, O'Fallon WM, Matteson EL. Evaluation of glucocorticosteroid injection for the treatment of trochanteric bursitis. *J Rheumatol* 1996;23:2104-2106.
5. Slawski DP, Howard RF. Surgical management of refractory trochanteric bursitis. *Am J Sports Med* 1997;25:86-89.
6. Anderson K, Strickland SM, Warren R. Hip and groin injuries in athletes. *Am J Sports Med* 2001;29:521-533.
7. Baker CL, Massie RV, Hurt WG, Savory CG. Arthroscopic bursectomy for recalcitrant trochanteric bursitis. *Arthroscopy* 2007;23:827-832.
8. Fox JL. The role of arthroscopic bursectomy in the treatment of trochanteric bursitis. *Arthroscopy* 2002;18:E34.
9. Mallow M, Nazarian LN. Greater trochanteric pain syndrome diagnosis and treatment. *Phys Med Rehabil Clin N Am* 2014;25:279-289.
10. Karpinski MRK, Piggott H. Greater trochanteric pain syndrome: A report of 15 cases. *J Bone Joint Surg Br* 1985;67:762-763.
11. Little H. Trochanteric bursitis: A common cause of pelvic girdle pain. *Can Med Assoc J* 1979;120:456-458.
12. Chowdhury R, Naaseri S, Lee J, Rajeswaran G. Imaging and management of greater trochanteric pain syndrome. *Postgrad Med J* 2014;90:576-581.
13. Del Buono A, Papalia R, Khanduja V, Denaro V, Maffulli N. Management of the greater trochanteric pain syndrome: A systematic review. *Br Med Bull* 2012;102:115-131.