

The Role of Meniscal Tears in Spontaneous Osteonecrosis of the Knee

A Systematic Review of Suspected Etiology and a Call to Revisit Nomenclature

Zaamin B. Hussain,* BA, Jorge Chahla,* MD, PhD, Bert R. Mandelbaum,† MD, Andreas H. Gomoll,‡ MD, PhD, and Robert F. LaPrade,*§|| MD, PhD
Investigation performed at the Steadman Philippon Research Institute, Vail, Colorado, USA

Background: The cause of spontaneous osteonecrosis of the knee (SONK) and postarthroscopic osteonecrosis of the knee is unknown, and the mechanisms involved have been poorly characterized.

Hypothesis/Purpose: The purpose of this study was to perform a detailed systematic review of the literature to examine proposed etiological mechanisms for SONK in order to establish an improved understanding of the processes involved. We hypothesized that the etiology of SONK would be multifactorial.

Study Design: Systematic review.

Methods: A systematic review of the literature was performed by searching PubMed, Medline, Cochrane Database of Systematic Reviews, and the Cochrane Central Register of Controlled Trials. Inclusion criteria were all original research articles presented in the English language that reported on the suspected etiology of SONK. Reviews, case reports with fewer than 3 patients, cost-effectiveness studies, technical reports, editorial articles, surveys, special topics, letters to the editor, personal correspondence, and studies that only proposed factors for the progression of SONK were excluded.

Results: After a comprehensive review of 255 articles, 26 articles were included for final analysis. Twenty-one (80.7%) of 26 articles implicated the role of the meniscus in the development of SONK, in an association with either meniscal tears or its development after meniscectomy. The medial meniscus and posterior meniscal root tears were implicated more frequently. All 4 studies incorporating histological findings supported the insufficiency fracture hypothesis as a pathological basis of SONK.

Conclusion: Physicians should be cognizant of the high prevalence of medial meniscus root tears in patients with SONK. Meniscectomy and meniscal tears, particularly of the medial meniscus posterior root, increase contact pressures and create an environment from which insufficiency fractures can emanate. We believe the term *SONK* is a misrepresentation of the etiology and pathogenesis of the condition and should be replaced with *subchondral insufficiency fractures of the knee*. Further elucidation of the etiology is required.

Keywords: spontaneous osteonecrosis of the knee; subchondral insufficiency fractures of the knee; meniscal tears; medial meniscus root tears; meniscectomy; postarthroscopic osteonecrosis; etiology

Osteonecrosis of the knee is a debilitating disease that can progress to end-stage osteoarthritis. Spontaneous osteonecrosis of the knee (SONK or SPONK) is 1 of 3 categories that are used to substratify osteonecrosis, the other 2 being secondary and postarthroscopic. SONK has been described as a focal, superficial subchondral lesion. While several risk factors have been proposed (including female sex,¹⁻³ age,^{2,3} cartilage degeneration,^{13,43} low bone mineral density [BMD],^{4,13,42} and medial meniscus posterior root tears^{30,33}), the precise etiology

is unknown and the pathological mechanisms involved remain poorly characterized, making effective management challenging.

The etiology and pathogenesis of SONK and postarthroscopic osteonecrosis remain highly controversial, and many theories have been proposed. Historically, SONK has been thought to occur secondary to ischemia, resulting in necrosis. Recently, however, a theory has been popularized proposing this entity to be a subchondral insufficiency fracture in osteopenic bone with no evidence of necrosis.¹⁶ These insufficiency fractures are thought to lead to fluid accumulation in the bone marrow, resulting in edema with focal ischemia and eventual necrosis.¹⁶ Factors predisposing to insufficiency fractures may include meniscal tears or meniscectomy, which can alter the native biomechanics

and increase contact pressures and stress concentration on weightbearing areas.¹⁶ Postarthroscopic osteonecrosis seems to follow a similar pathogenesis.²⁶ Therefore, the purpose of this study was to perform a detailed systematic review of the literature to evaluate studies that suggest etiological mechanisms for SONK in order to establish an improved understanding. We hypothesized that the etiology of SONK would be multifactorial.

METHODS

Article Identification and Selection

The study was conducted in accordance with the 2009 Preferred Reporting Items for Systematic Review and Meta-analysis (PRISMA) statement.²¹ A systematic review of the literature regarding the etiology of SONK was performed using PubMed, Medline, the Cochrane Database of Systematic Reviews, and the Cochrane Central Register of Controlled Trials, with the following search criteria: {(Spontaneous Osteonecrosis) or SPONK or SONK or SO} OR [(post or after) and arthroscopy and ((avascular necrosis) or osteonecrosis)] AND Knee. The queries were performed in June 2017.

All original research articles published in English that reported on the suspected etiology of SONK were included. Reviews, case reports with fewer than 3 patients, cost-effectiveness studies, technical reports, editorial articles, surveys, special topics, letters to the editor, and personal correspondence were excluded. Studies that proposed factors for the progression of SONK were excluded, as the aim of this study was to investigate the etiology of the onset of SONK.

Two investigators (Z.B.H., J.C.) independently reviewed the titles from all identified articles, and unrelated titles were excluded. Abstracts were subsequently reviewed, and full-text articles were obtained for review to allow for further assessment of inclusion or exclusion criteria. References from the included studies were reviewed to reduce the risk of omission of relevant articles.

Data Collection

Data were recorded into a custom information extraction table. Data were collected on the proposed etiology of SONK, specifically collecting level of evidence, study design, patient demographic data in the study, outcome measures used, principal findings, and the proposed hypothesis for SONK.

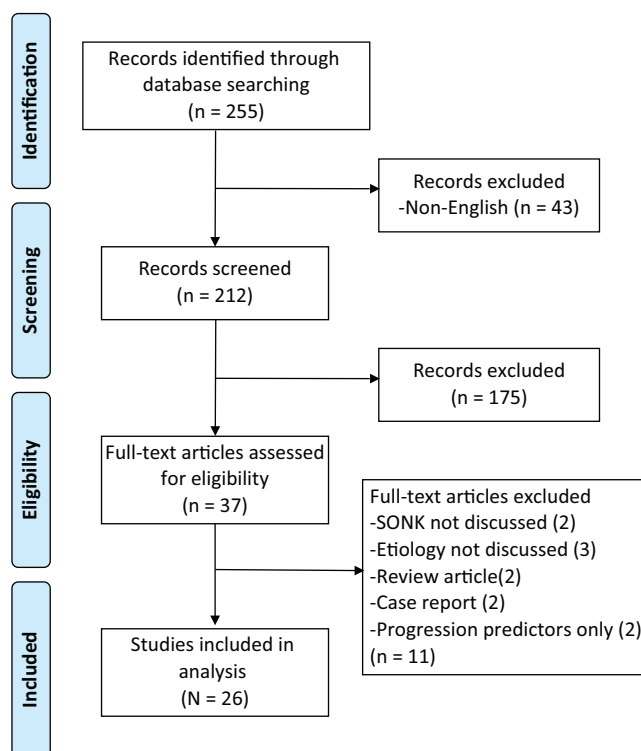


Figure 1. Preferred Reporting Items for Systematic Review and Meta-analysis (PRISMA) flowchart demonstrating the selection criteria and reasons for exclusions.

RESULTS

Article Identification and Selection

The process for study selection is presented in Figure 1. The search strategy identified 255 individual reports. After application of inclusion and exclusion criteria, 218 studies were eliminated, leaving 37 articles for full-text review. After a comprehensive review of these articles, a total of 26 articles met the inclusion criteria for analysis.

Demographic Data

Twenty-six articles were included in the final analysis, with year of publication between 1978 and 2017. Four basic science studies were included. Level of evidence for the clinical studies was level 4 in 14 articles, level 3 in 6 articles, and level 2 in 2 articles. The total number of

^{||}Address correspondence to Robert F. LaPrade, MD, PhD, The Steadman Clinic, 181 West Meadow Drive, Suite 1000, Vail, CO 81657, USA (email: rlaprade@thesteadmanclinic.com).

^{*}Steadman Philippon Research Institute, Vail, Colorado, USA.

[†]Santa Monica Orthopaedic Group, Santa Monica, California, USA.

[‡]Cartilage Repair Center and Center for Regenerative Medicine, Brigham and Women's Hospital, Harvard Medical School, Harvard University, Boston, Massachusetts, USA.

[§]The Steadman Clinic, Vail, Colorado, USA.

One or more of the authors has declared the following potential conflict of interest or source of funding: R.F.L. receives royalties from Arthrex Inc, and Smith & Nephew; is a paid consultant for Arthrex Inc, Ossur, and Smith & Nephew; and receives research support from Arthrex Inc, Smith & Nephew, Ossur, and Linvatec. B.R.M. is a paid consultant for Arthrex Inc, DePuy, Exactech Inc, and Regen Biologics and receives IP royalties from Arthrex Inc. A.H.G. is a paid consultant for NuTech, Cartiheel, JRF, and Vericel; receives royalties from NuTech; receives research support from NuTech, JRF, and SBM; and is a paid speaker for Smith & Nephew.

TABLE 1
Basic Science Studies and Histological Findings^a

Study	Year of Publication	No. of Patients	Key Findings/Hypothesis for Etiology
Yamamoto and Bullough ³⁹	2000	14	Histological analysis suggests insufficiency fractures caused SONK
Mears et al ²⁰	2009	21	
Tanaka et al ³⁴	2009	6	Histological analysis shows subchondral fractures permitting fluid infiltration; all patients had evidence of radial or degenerative tears with medial displacement of the medial meniscus
Higuchi et al ¹²	2013	6	Histological analysis suggests insufficiency fractures caused SONK after meniscectomy

^aSONK, spontaneous osteonecrosis of the knee.

patients across all included studies was 749. The mean of the mean ages given in each study was 60.4 years (range, 33-73 years).

Basic Science Studies and Histological Findings

All 4 studies reporting histological findings supported the insufficiency fracture hypothesis for the pathological basis of SONK (Table 1).

Meniscal Tears

Thirteen studies suggested an association between meniscal tears and SONK and, hence, a possible role in the etiology and pathogenesis. The medial meniscus was implicated more frequently, explicitly in 12 studies (92%), and the tear side was not mentioned in the remaining study.²⁴ Regarding tear-pattern type, posterior meniscal root tears were explicitly implicated in 5 studies (38%), and 4 out of 5 of these were published in 2009 or later (Table 2).

Meniscectomy

Eight studies reported the development of SONK after arthroscopic meniscectomy, thereby suggesting a possible role in the etiology and pathogenesis (Table 3).

Other Arthroscopic Procedures

One study reported the development of SONK after arthroscopic laser or radiofrequency treatment, and another study reported SONK after anterior cruciate ligament (ACL) reconstruction (Table 4).

BMD

Akamatsu et al⁴ reported the possible role of low BMD in the etiology of SONK; however, it was suggested this was not likely to be an etiological mechanism by Nelson et al²⁴ (Table 5).

DISCUSSION

The most important finding of this study was that 21 out of 26 included studies implicated the role of the meniscus in the development of SONK. This occurred in association with either meniscal tears or meniscectomy. For the reasons described below, we suggest the term *SONK* should be abandoned and *subchondral insufficiency fractures of the knee (SIFK)* should be adopted.

All 4 histopathological studies supported the insufficiency fracture theory for the development of SONK. Yamamoto and Bullough³⁹ first described subchondral insufficiency fractures as the primary events leading to SONK, based on gross and histological findings in 14 patients with SONK. These insufficiency fractures were hypothesized to lead to fluid accumulation in the bone marrow, resulting in subsequent edema with focal ischemia and eventual necrosis. In addition, Tanaka et al³⁴ found articular bone plate insufficiency fractures with endochondral ossification, reactive cartilage tissue formation, and proliferation of fibrous tissue. Moreover, Higuchi et al¹² suggested that postmeniscectomy osteonecrosis may result from subchondral bone fractures, based on patients who displayed juxta-articular bone marrow signal changes. This study also suggested that because fracture healing is impaired in patients with comorbidities (eg, hyperlipidemia, hypertension, diabetes mellitus), background disease may be a risk factor for osteonecrosis. Although these studies report a potential mechanism for the pathogenesis of SONK, they fail to indicate specific triggers that may lead its development.

Ten of the 13 studies implicating meniscal tears reported the prevalence of meniscal tears in SONK patients[¶] and found these to occur in a range of 50% to 100% of patients, suggesting a strong association between meniscal lesions and SONK. It was also noted that posterior root tears of the medial meniscus were associated with SONK in 5 studies.^{24,30,33,38,40} The hoop mechanism of the menisci facilitates load distribution, force absorption, lubrication, and stabilization. However, the medial meniscus has less inherent mobility due to its robust attachment to the medial tibial plateau,^{8,19} and it carries

[¶]References 11, 24, 25, 27, 29, 30, 36, 38, 40, 41.

TABLE 2
Studies Implicating a Role for Meniscal Tears in the Etiology of SONK^a

Study	Year of Publication	Level of Evidence	No. of Patients	Key Findings/Hypothesis for Etiology
Norman and Baker ²⁵	1978	4	27	78% of patients with SONK had medial meniscal tears
Valenti Nin et al ³⁶	1998	4	21	50% of patients who underwent surgery for SONK treatment had medial meniscal injury
Ramnath and Kattapuram ²⁹	2004	4	39	Medial meniscal tears in 82%, cartilage defects in 64% of patients with SONK with linear components seen on MRI; meniscal tears in 76%, cartilage defects in 98% of patients with SONK with nonlinear components seen on MRI
Yao et al ⁴⁰	2004	3	25	76% of patients with SONK had meniscal tears; radial and posterior root tears of the medial meniscus were more common (found in 53%)
Muscolo et al ²²	2006	4	5	MRI changes suggestive of SONK after a medial meniscal tear
Robertson et al ³⁰	2009	4	30	80% of patients with SONK had tears of posterior root of medial meniscus (63% complete, 37% partial); complete tears associated with >3 mm of meniscal extrusion
Tanaka et al ^{34b}	2009	Basic science	6	Histological analysis shows subchondral fractures allowing fluid infiltration; all patients had evidence of radial or degenerative tears with medial extrusion of the medial meniscus
Sung et al ³³	2013	3	63	Incidence of SONK was 33% in the root tear group, 14.8% in horizontal tear group (all tears of medial meniscus); mean absolute extrusion was 4.1 mm in the root tear vs 3.5 mm in the horizontal tear groups (not significant)
Nelson et al ²⁴	2014	4	32	88% of patients with SONK had meniscal tears (9 posterior root, 22 degenerative or complex tears); side of meniscal tears not reported; 63% had meniscal extrusion of 3 mm or more
Plett et al ²⁷	2015	4	73	Ipsilateral meniscal injury observed in 94% of patients with SONK, 89% on medial femoral condyle, full-thickness cartilage loss in 76%
Chambers et al ¹¹	2015	3	23	92% of SONK knees had a medial meniscal tear
Yamagami et al ³⁸	2017	3	45	Medial meniscus posterior root tears found in 62% of patients with SONK, compared with 34% of patients with osteoarthritis
Yasuda et al ⁴¹	2017	4	18	All patients (100%) with SONK showed substantial extrusion (>3 mm) and degeneration of medial meniscus

^aMRI, magnetic resonance imaging; SONK, spontaneous osteonecrosis of the knee.

^bDenotes the study has been included in more than one table.

more force during weightbearing. Consequently, it is more vulnerable to tearing and degeneration. In addition, the posterior horn of the meniscus has been shown to carry more load than the anterior horn through its strong, bony insertion.¹⁵ Therefore, disruption of the posterior medial meniscus root can result in a loss of hoop tension, increased contact pressures, and subsequent alteration of normal knee biomechanics, bearing similarities to the biomechanics seen in total meniscectomy.⁵ Additionally, medial meniscal root tears have been hypothesized to increase the peak pressure of the femoral condyle more than horizontal tears of the posterior horn.³³ The resulting increased contact pressures would provide an etiological mechanism for the insufficiency fracture theory as described above.

Eight studies reported the development of SONK after arthroscopic meniscectomy.^{10,12,14,17,23,28,31,35} Postarthroscopic osteonecrosis has classically been considered a separate subcategory of osteonecrosis; however, in context of the association specifically with arthroscopic meniscectomy, this review suggests that the etiology and pathogenesis are likely similar. This hypothesis is further validated by

findings reporting that a knee without a medial meniscus experiences twice the peak pressures with loading as compared with a knee with an intact meniscus.³² Therefore, the increased tibiofemoral contact pressures after meniscectomy could lead to subchondral insufficiency fractures from altered load transmission.

Other arthroscopic procedures have been implicated in SONK, such as laser therapy and ACL reconstruction. Bonutti et al⁹ reported several cases of SONK after laser or radiofrequency-assisted arthroscopy. Experimental studies in both humans and animals have shown that osteonecrosis may develop if thermal exposure of the bone exceeds temperatures of 50°C to 70°C for as short a time as 1 minute,^{6,7} and the vulnerability of cartilage and subchondral bone to the effects of thermal exposure is a major concern in laser-assisted arthroscopy. In this way, the mechanism of pathogenesis of SONK in these particular cases may be entirely different. However, medial meniscal tears were reported in 53% of cases and lateral meniscal tears in 21%. The precise arthroscopic procedures performed with laser or radiofrequency were not reported, but in context

TABLE 3
Studies Implicating a Role for Meniscectomy in the Etiology of SONK^a

Study	Year of Publication	Level of Evidence	No. of Patients	Key Findings/Hypothesis for Etiology
Brahme et al ¹⁰	1991	4	7	MRI changes suggestive of SONK after meniscal injury and arthroscopic partial meniscectomy
Muscolo et al ²³	1996	4	8	MRI changes suggestive of SONK after arthroscopic medial meniscectomy (3 partial, 5 total); altered biomechanics hypothesized
Prues-Latour et al ²⁸	1998	4	9	MRI changes observed 6-48 weeks postoperatively; SONK development on medial condyle, 89% were after arthroscopic medial meniscectomy
Johnson et al ¹⁴	2000	4	7	All patients with SONK received arthroscopic partial meniscectomy (4 medial, 2 lateral) or chondroplasty
Kobayashi et al ¹⁷	2002	3	93	MRI changes suggestive of SONK after arthroscopic meniscectomy in 34%: 57 partial (34 medial, 23 lateral) and 36 total (10 medial, 26 lateral)
Schmid et al ³¹	2011	2	24	Biomechanical assessment showed meniscectomy increased the maximum contact stresses over the critical threshold of the compressive strength in cancellous bone; meniscectomy has a role in the etiology of SONK
Higuchi et al ^{12b}	2013	Basic science	6	Histological analysis suggests insufficiency fractures caused SONK after meniscectomy
Turker et al ³⁵	2015	2	75	MRI changes suggestive of SONK after arthroscopic meniscectomy; no additional risk with mechanical debridement or chondroplasty

^aMRI, magnetic resonance imaging; SONK, spontaneous osteonecrosis of the knee.

^bDenotes the study has been included in more than one table.

TABLE 4
Studies Implicating a Role for Other Arthroscopic Procedures in the Etiology of SONK^a

Study	Year of Publication	Level of Evidence	No. of Patients	Key Findings/Hypothesis for Etiology
Bonutti et al ⁹	2006	4	19	Development of SONK after holmium or YAG laser or radiofrequency-assisted arthroscopy; details of arthroscopic procedure not reported; medial meniscal tear in 53%, lateral meniscal tear in 21%, chondromalacia in 58%
Lansdown et al ¹⁸	2015	4	5	Development of SONK after ACL reconstruction (2 isolated reconstructions and 3 patients with concomitant meniscal procedures: meniscal debridement, partial medial meniscectomy, and lateral meniscal repair)

^aACL, anterior cruciate ligament; SONK, spontaneous osteonecrosis of the knee.

TABLE 5
Studies Investigating a Role for BMD in the Etiology of SONK^a

Study	Year of Publication	Level of Evidence	No. of Patients	Key Findings/Hypothesis for Etiology
Akamatsu et al ⁴	2012	3	52	Lower BMD in patients with SONK in femoral neck, lateral femoral condyle, and lateral tibial condyle compared with patients with medial knee OA
Nelson et al ²⁴	2014	4	32	Only 16% of patients with SONK had osteoporosis, suggesting this was not the underlying cause

^aBMD, bone mineral density; OA, osteoarthritis; SONK, spontaneous osteonecrosis of the knee.

of these injuries, meniscal treatment is likely to have been involved. It is therefore possible that although laser or radiofrequency may appear to be associated with SONK, the meniscus condition and treatment may actually be a confounding factor, as hypothesized above. In addition, Lansdown et al¹⁸ described 5 cases of atypical bicondylar osteonecrosis after ACL reconstruction with a mean patient age of 33 years. However, 3 of the 5 cases had concomitant

meniscal procedures, again potentially acting as a confounding factor for SONK.

Nomenclature in the literature surrounding SONK is variable, adding further complexity to the topic. In an attempt to revise the nomenclature, Yao et al⁴⁰ adopted the term *presumptive subarticular stress reactions of the knee*, considered synonymous with SONK; however, this term has not been embraced by the wider scientific

community. Recently, the insufficiency fracture theory for pathogenesis of SONK has become so ingrained that several studies have replaced SONK with *subchondral insufficiency fractures of the knee (SIFK)*.^{27,37} In addition, the term SONK has been criticized as inappropriate given that this condition is not likely to be “spontaneous,” as further validated by this review, but rather seems to display alternative pathologic findings to traditional ischemia-induced osteonecrosis, as seen in other joints including the hip. In fact, Mears et al²⁰ found that only 1 of 22 knees with SONK demonstrated any evidence of bone death and argued the condition had been “misnamed.” The variable and possibly inappropriate nomenclature used to describe this condition has the potential to stifle progression in elucidating the true etiology and pathogenesis involved, which is why we suggest the term SONK should be abandoned and *subchondral insufficiency fractures of the knee (SIFK)* adopted, with further research required to elucidate its etiological mechanisms.

This study is not without limitations. Given that medial meniscal root tears have only become recognized by the orthopaedic and radiological community over the past 7 to 10 years,⁸ it is possible that studies published before this time reporting on “medial meniscal tears” may have in fact been reporting on undiagnosed medial meniscal posterior root tears. Factors such as the etiology and pathological mechanisms involved in the development of SONK are likely to be complex and multifactorial, and one key challenge is making the differentiation between etiological factors, risk factors, and predictors of progression. We have identified the meniscus to have a key role in the development of SONK; however, given the relatively low levels of evidence of the included studies, we can only suggest meniscal lesions and SONK are associated, and a causative relationship does not necessarily exist. It remains possible that confounding factors are yet to be exposed—not all meniscal lesions progress to SONK and not all patients with SONK demonstrate meniscal lesions, suggesting there are other factors at play. This should be the topic of further research.

CONCLUSION

SONK is likely to be multifactorial, although meniscectomy and meniscal tears, particularly of the medial posterior root, increase contact pressures and create an environment from which insufficiency fractures can emanate. Physicians should be cognizant of the high prevalence of medial meniscal root tears in patients presenting with SONK. We believe the term SONK is a misrepresentation of the etiology and pathogenesis of the condition and should be replaced with *subchondral insufficiency fractures of the knee (SIFK)*. Further elucidation of the etiology is required.

REFERENCES

1. Aglietti P, Insall JN, Buzzi R, Deschamps G. Idiopathic osteonecrosis of the knee. Aetiology, prognosis and treatment. *J Bone Joint Surg Br*. 1983;65(5):588-597.

2. Ahlback S, Bauer GC, Bohne WH. Spontaneous osteonecrosis of the knee. *Arthritis Rheum*. 1968;11(6):705-733.
3. Akamatsu Y, Kobayashi H, Kusayama Y, Aratake M, Kumagai K, Saito T. Predictive factors for the progression of spontaneous osteonecrosis of the knee. *Knee Surg Sports Traumatol Arthrosc*. 2017;25(2):477-484.
4. Akamatsu Y, Mitsugi N, Hayashi T, Kobayashi H, Saito T. Low bone mineral density is associated with the onset of spontaneous osteonecrosis of the knee. *Acta Orthop*. 2012;83(3):249-255.
5. Allaire R, Muriuki M, Gilbertson L, Harner CD. Biomechanical consequences of a tear of the posterior root of the medial meniscus. Similar to total meniscectomy. *J Bone Joint Surg Am*. 2008;90(9):1922-1931.
6. Andersen E, Bruun C. Temperatures measured during reaming of the femoral neck and head. A preliminary report. *Clin Orthop Relat Res*. 1989;241:200-202.
7. Berman AT, Reid JS, Yanicko DR Jr, Sih GC, Zimmerman MR. Thermally induced bone necrosis in rabbits. Relation to implant failure in humans. *Clin Orthop Relat Res*. 1984;186:284-292.
8. Bhatia S, LaPrade CM, Ellman MB, LaPrade RF. Meniscal root tears: significance, diagnosis, and treatment. *Am J Sports Med*. 2014;42(12):3016-3030.
9. Bonutti PM, Seyler TM, Delanois RE, McMahon M, McCarthy JC, Mont MA. Osteonecrosis of the knee after laser or radiofrequency-assisted arthroscopy: treatment with minimally invasive knee arthroplasty. *J Bone Joint Surg Am*. 2006;88(suppl 3):69-75.
10. Brahme SK, Fox JM, Ferkel RD, Friedman MJ, Flannigan BD, Resnick DL. Osteonecrosis of the knee after arthroscopic surgery: diagnosis with MR imaging. *Radiology*. 1991;178(3):851-853.
11. Chambers C, Craig JG, Zvirbulis R, Nelson F. Spontaneous osteonecrosis of knee after arthroscopy is not necessarily related to the procedure. *Am J Orthop (Belle Mead NJ)*. 2015;44(6):E184-E189.
12. Higuchi H, Kobayashi Y, Kobayashi A, Hatayama K, Kimura M. Histologic analysis of postmeniscectomy osteonecrosis. *Am J Orthop (Belle Mead NJ)*. 2013;42(5):220-222.
13. Houpt JB, Pritzker KP, Alpert B, Greyson ND, Gross AE. Natural history of spontaneous osteonecrosis of the knee (SONK): a review. *Semin Arthritis Rheum*. 1983;13(2):212-227.
14. Johnson TC, Evans JA, Gilley JA, DeLee JC. Osteonecrosis of the knee after arthroscopic surgery for meniscal tears and chondral lesions. *Arthroscopy*. 2000;16(3):254-261.
15. Kan A, Oshida M, Oshida S, Imada M, Nakagawa T, Okinaga S. Anatomical significance of a posterior horn of medial meniscus: the relationship between its radial tear and cartilage degradation of joint surface. *Sports Med Arthrosc Rehabil Ther Technol*. 2010;2:1.
16. Karim AR, Cherian JJ, Jauregui JJ, Pierce T, Mont MA. Osteonecrosis of the knee: review. *Ann Transl Med*. 2015;3(1):6.
17. Kobayashi Y, Kimura M, Higuchi H, Terauchi M, Shirakura K, Takagishi K. Juxta-articular bone marrow signal changes on magnetic resonance imaging following arthroscopic meniscectomy. *Arthroscopy*. 2002;18(3):238-245.
18. Lansdown DA, Shaw J, Allen CR, Ma CB. Osteonecrosis of the knee after anterior cruciate ligament reconstruction: a report of 5 cases. *Orthop J Sports Med*. 2015;3(3):2325967115576120.
19. LaPrade RF, Engebretsen AH, Ly TV, Johansen S, Wentorf FA, Engebretsen L. The anatomy of the medial part of the knee. *J Bone Joint Surg Am*. 2007;89(9):2000-2010.
20. Mears SC, McCarthy EF, Jones LC, Hungerford DS, Mont MA. Characterization and pathological characteristics of spontaneous osteonecrosis of the knee. *Iowa Orthop J*. 2009;29:38-42.
21. Moher D, Liberati A, Tetzlaff J, Altman DG, Group P. Preferred reporting items for systematic reviews and meta-analyses: the PRISMA statement. *Ann Intern Med*. 2009;151(4):264-269, W264.
22. Muscolo DL, Costa-Paz M, Ayerza M, Makino A. Medial meniscal tears and spontaneous osteonecrosis of the knee. *Arthroscopy*. 2006;22(4):457-460.
23. Muscolo DL, Costa-Paz M, Makino A, Ayerza MA. Osteonecrosis of the knee following arthroscopic meniscectomy in patients over 50-years old. *Arthroscopy*. 1996;12(3):273-279.

24. Nelson FR, Craig J, Francois H, Azuh O, Oyetakin-White P, King B. Subchondral insufficiency fractures and spontaneous osteonecrosis of the knee may not be related to osteoporosis. *Arch Osteoporos*. 2014;9:194.
25. Norman A, Baker ND. Spontaneous osteonecrosis of the knee and medial meniscal tears. *Radiology*. 1978;129(3):653-656.
26. Pape D, Seil R, Anagnostakos K, Kohn D. Postarthroscopic osteonecrosis of the knee. *Arthroscopy*. 2007;23(4):428-438.
27. Plett SK, Hackney LA, Heilmeier U, et al. Femoral condyle insufficiency fractures: associated clinical and morphological findings and impact on outcome. *Skeletal Radiol*. 2015;44(12):1785-1794.
28. Prues-Latour V, Bonvin JC, Fritschy D. Nine cases of osteonecrosis in elderly patients following arthroscopic meniscectomy. *Knee Surg Sports Traumatol Arthrosc*. 1998;6(3):142-147.
29. Ramnath RR, Kattapuram SV. MR appearance of SONK-like subchondral abnormalities in the adult knee: SONK redefined. *Skeletal Radiol*. 2004;33(10):575-581.
30. Robertson DD, Armfield DR, Towers JD, Irrgang JJ, Maloney WJ, Harner CD. Meniscal root injury and spontaneous osteonecrosis of the knee: an observation. *J Bone Joint Surg Br*. 2009;91(2):190-195.
31. Schmid RB, Wirz D, Gopfert B, Arnold MP, Friederich NF, Hirschmann MT. Intra-operative femoral condylar stress during arthroscopy: an in vivo biomechanical assessment. *Knee Surg Sports Traumatol Arthrosc*. 2011;19(5):747-752.
32. Song Y, Greve JM, Carter DR, Koo S, Giori NJ. Articular cartilage MR imaging and thickness mapping of a loaded knee joint before and after meniscectomy. *Osteoarthritis Cartilage*. 2006;14(8):728-737.
33. Sung JH, Ha JK, Lee DW, Seo WY, Kim JG. Meniscal extrusion and spontaneous osteonecrosis with root tear of medial meniscus: comparison with horizontal tear. *Arthroscopy*. 2013;29(4):726-732.
34. Tanaka Y, Mima H, Yonetani Y, Shiozaki Y, Nakamura N, Horibe S. Histological evaluation of spontaneous osteonecrosis of the medial femoral condyle and short-term clinical results of osteochondral autografting: a case series. *Knee*. 2009;16(2):130-135.
35. Turker M, Cetik O, Cirpar M, Durusoy S, Comert B. Postarthroscopy osteonecrosis of the knee. *Knee Surg Sports Traumatol Arthrosc*. 2015;23(1):246-250.
36. Valenti Nin JR, Leyes M, Schweitzer D. Spontaneous osteonecrosis of the knee. Treatment and evolution. *Knee Surg Sports Traumatol Arthrosc*. 1998;6(1):12-15.
37. Wilmot AS, Ruutiainen AT, Bakhru PT, Schweitzer ME, Shabshin N. Subchondral insufficiency fracture of the knee: a recognizable associated soft tissue edema pattern and a similar distribution among men and women. *Eur J Radiol*. 2016;85(11):2096-2103.
38. Yamagami R, Taketomi S, Inui H, Tahara K, Tanaka S. The role of medial meniscus posterior root tear and proximal tibial morphology in the development of spontaneous osteonecrosis and osteoarthritis of the knee. *Knee*. 2017;24(2):390-395.
39. Yamamoto T, Bullough PG. Spontaneous osteonecrosis of the knee: the result of subchondral insufficiency fracture. *J Bone Joint Surg Am*. 2000;82(6):858-866.
40. Yao L, Stanczak J, Boutin RD. Presumptive subarticular stress reactions of the knee: MRI detection and association with meniscal tear patterns. *Skeletal Radiol*. 2004;33(5):260-264.
41. Yasuda T, Ota S, Fujita S, Onishi E, Iwaki K, Yamamoto H. Association between medial meniscus extrusion and spontaneous osteonecrosis of the knee [published online April 5, 2017]. *Int J Rheum Dis*. doi:10.1111/1756-185X.13074.
42. Zanetti M, Romero J, Dambacher MA, Hodler J. Osteonecrosis diagnosed on MR images of the knee. Relationship to reduced bone mineral density determined by high resolution peripheral quantitative CT. *Acta Radiol*. 2003;44(5):525-531.
43. Zywił MG, McGrath MS, Seyler TM, Marker DR, Bonutti PM, Mont MA. Osteonecrosis of the knee: a review of three disorders. *Orthop Clin North Am*. 2009;40(2):193-211.