

# Return to Play After Hip Arthroscopic Surgery for Femoroacetabular Impingement in Professional Soccer Players

Renato Locks,\* MD, Hajime Utsunomiya,\* MD, PhD, Karen K. Briggs,\* MPH, Shannen McNamara,\* BS, Jorge Chahla,\* MD, and Marc J. Philippon,\*<sup>†</sup> MD

*Investigation performed at the Steadman Philippon Research Institute, Vail, Colorado, USA*

**Background:** Arthroscopic hip surgery has been shown to be effective in returning professional athletes back to play at a high level of performance in different sports. Limited information exists regarding professional soccer players and their return to play.

**Purpose:** To determine the rate and time to return to sport for professional soccer players after hip arthroscopic surgery for the treatment of femoroacetabular impingement (FAI) and to identify possible risk factors associated with a delay in returning to play.

**Study Design:** Case series; Level of evidence, 4.

**Methods:** Professional soccer players who underwent hip arthroscopic surgery for FAI by a single surgeon between 2005 and 2015 were evaluated. Data retrieved from [www.mlssoccer.com](http://www.mlssoccer.com), [www.fifa.com](http://www.fifa.com), [www.transfermarkt.co.uk](http://www.transfermarkt.co.uk), and [www.wikipedia.org](http://www.wikipedia.org) included information on each player's professional career, participation on the national team, length of professional career before surgery, number of appearances (games) before surgery, time between surgery and first appearance in a professional game, and number of appearances after surgery. Other data were obtained from the patient's medical records.

**Results:** Twenty-four professional soccer players (26 hips) were included. The mean age at surgery was  $25.0 \pm 4.0$  years (range, 19-32 years). A total of 96% of patients were able to return to play at the professional level. The mean time between surgery and the first professional game played was 9.2 months (range, 1.9-24.0 months). On average, players played in 70 games after surgery (range, 0-224). National team players were able to return to play significantly earlier than the rest of the players (median, 5.7 months vs 11.6 months, respectively;  $P = .018$ ). Severe chondral damage and microfracture did not interfere with return to play.

**Conclusion:** The arthroscopic management of FAI in symptomatic professional soccer players allowed 96% of them to return to play. Players with national team experience were able to return to play earlier than those without it. Severe chondral damage and microfracture did not interfere with return to play.

**Keywords:** soccer; femoroacetabular impingement; hip; return to play

Soccer is played by more than 200 million players in over 200 countries, making it the most popular sport in the world.<sup>7</sup> Injury incidence among soccer players is widely documented; the match injury incidence in adults was reported to be up to 30 per 1000 hours, and the training injury incidence was reported to be about 5 per 1000 hours of exposure.<sup>8</sup> Hip and groin injuries are relatively common in soccer. A

systematic review of male elite soccer players reported that the incidence of hip injuries ranged between 11% and 16% of total injuries.<sup>19</sup> Over the course of the past 2 decades, the recognition, diagnosis, and treatment of injuries of the hip region have increased dramatically, mainly in the athletic population.<sup>8,11,15,25</sup> Diagnoses that have recently received the most attention include adductor injuries, sports hernias, and femoroacetabular impingement (FAI).

FAI of the hip joint has been identified as a cause of hip pain, reduced range of motion, and decreased performance in the athlete.<sup>16,21,23</sup> This loss of function and performance is because of chondral and labral damage and loss of motion caused by FAI. Cam-type deformities have been reported in young club soccer players at a higher prevalence compared with controls of the same age who did not participate in sports and were selected from a radiology database.<sup>1</sup> The study also reported that cam-type deformities were present at 13 years and develop when the physis closes. It is unclear if this is caused by high-intensity sports, the number of years played, or repeated stress on

<sup>†</sup>Address correspondence to Marc J. Philippon, MD, Steadman Philippon Research Institute, 181 West Meadow Drive, Suite 400, Vail, CO 81657, USA (email: [drphilippon@sprivail.org](mailto:drphilippon@sprivail.org)).

\*Steadman Philippon Research Institute, Vail, Colorado, USA.

One or more of the authors has declared the following potential conflict of interest or source of funding: M.J.P. receives consulting/royalty payments from Smith & Nephew, Arthrosurface, MJP Innovations, MIS, Bledsoe, DonJoy, and ConMed Linvatec and receives research or other financial support from Smith & Nephew, Ossur, Arthrex, and Siemens.

the physis when the hip is in an “at-risk” position. Other conditions that may lead to FAI include congenital deformities, posttraumatic deformities, coxa profunda, acetabular retroversion, and protrusio acetabuli.<sup>18</sup>

Arthroscopic hip surgery has been shown to be effective in returning professional athletes back to play at a high level of performance in different sports.<sup>2-6,10,12-14,17,20</sup> The return-to-play rate has been reported for hockey,<sup>14</sup> baseball,<sup>6</sup> and football.<sup>13</sup> However, information is lacking regarding professional soccer players and their return to play after hip arthroscopic surgery for the treatment of FAI. The purpose of this study was to determine the return-to-sport rate and length of career in professional soccer players after hip arthroscopic surgery for the treatment of FAI and to identify factors associated with not returning to play. The hypothesis was that a high percentage of professional soccer players would return to play at a high level of performance after hip arthroscopic surgery for symptomatic FAI.

## METHODS

### Patient Selection and Demographic Data

This study was approved by an institutional review board. Between 2005 and 2015, 24 professional soccer players who had symptomatic FAI that was treated with hip arthroscopic surgery by a single surgeon (M.J.P.) were included in this study. A professional soccer player was defined as an athlete who appeared in the national league or a cup game or was valued by a transfer fee. Soccer players receive a transfer fee when they become attached to a professional team. The transfer fee is the compensation paid for a player's rights and is usually higher based on the player's skill level. Patients were excluded if they had officially retired from professional soccer before hip arthroscopic surgery.

### Diagnosis

Patients underwent a thorough history and physical examination of the hip at the time of the initial presentation. Clinical symptoms included pain and/or other mechanical symptoms isolated to the hip. The inability to continue to play professional soccer due to hip symptoms was noted in all patients. The clinical diagnosis of FAI was based on physical examination findings indicative of FAI, which included a positive anterior impingement sign (pain with flexion, adduction, and internal rotation) and/or a positive FABER (flexion, abduction, and external rotation) test result.

Radiographs were obtained for all patients, consisting of anteroposterior pelvis, false profile, and Dunn views. Advanced imaging, including noncontrast magnetic resonance imaging, was used to evaluate the presence of labral tears, chondral injuries, soft tissue lesions, or other pathological changes in or around the hip joint. The radiographic diagnosis of FAI was based on a crossover sign for pincer impingement and an alpha angle  $>55^\circ$  for cam impingement. All soccer players included in the study had both clinical and radiographic findings for FAI. All patients had failed a course of nonoperative management.

## Operative Technique

Arthroscopic surgery on all patients was performed by a single surgeon. Patients were placed in the supine position on a standard traction table under spinal-epidural anesthesia with the operative leg in neutral coronal alignment,  $15^\circ$  of flexion, and maximal internal rotation. Manual traction was applied to distract the hip joint approximately 1 cm, confirmed using fluoroscopy. The procedure then began by establishing standard anterolateral and midanterior portals to allow access to the central compartment. Surgical treatment included acetabular rim trimming, subspine decompression, femoral neck osteoplasty,<sup>22</sup> acetabular microfracture, and/or labral repair versus reconstruction with an iliotibial band autograft. Labral reconstruction was performed if there was an irreparable tear of the labrum or there was insufficient labral tissue, which disrupted the fluid seal between the labrum and the femoral head.<sup>9</sup> The extent of the correction of impingement was based on a dynamic bony impingement examination. Partial capsular closure was performed at the end of the procedure in all patients.

### Postoperative Rehabilitation

After surgery, all athletes were limited to 10-kg toe-touch weightbearing on the operative leg, with 4 hours of continuous passive motion daily for the first 4 weeks. When microfracture was performed, the weightbearing restrictions and continuous passive motion were extended for a total of 7 weeks. Supervised physical therapy was started on postoperative day 1, beginning with passive range of motion. Hip circumduction exercises were also utilized to reduce the risk of intra-articular adhesion formation.<sup>24</sup> The athletes were then progressed to active range of motion, followed by strengthening and endurance exercises. Progressive functional (and sport-specific) rehabilitation helps the patient to return to full activity, while the actual decision is based on several objectives (functional tests) and subjective factors.

### Player Performance Characteristics

Data were retrieved from [www.mlssoccer.com](http://www.mlssoccer.com), [www.fifa.com](http://www.fifa.com), [www.transfermarkt.co.uk](http://www.transfermarkt.co.uk), and [www.wikipedia.org](http://www.wikipedia.org), including information on each player's professional career, participation on the national team, length of professional career before surgery, number of appearances (games) before surgery, time between surgery and first appearance in a professional game, and number of appearances after surgery. In addition, position played and dominant side were documented. Patient age, date of onset, and if the player had undergone previous surgery were collected from the patient chart.

### Surgical Findings

Intraoperative findings (including labral and chondral pathological changes) and surgical details were recorded. Surgical details included the type of FAI (cam, pincer, or mixed), primary or revision surgery, labral treatment (debridement,

TABLE 1  
Demographics Before and After Surgery<sup>a</sup>

No.	Position	National Team Experience	Age at Surgery, y	Previous Hip Surgery	Soccer Experience Before Surgery, y	No. of Games Before Surgery	Time From Onset to Surgery, mo	Return to Professional Soccer	Time From Surgery to First Game, mo	Playing Status in December 2016	No. of Games After Surgery	Time From Surgery to End of Career, y
1	DF	No	19	Yes	1	3	7	Yes	23.2	Retired	6	3
2	DF	No	23	No	5	28	12	Yes	10.1	Retired	224	10
3	DF	Yes	26	No	9	273	1	Yes	2.5	Retired	174	7
4	DF	Yes	20	No	0	1	1	Yes	11.6	Active	49	2
5	DF	Yes	26	No	13	254	2	Yes	5.2	Active	13	1
6	FW	Yes	24	No	5	77	13	Yes	5.5	Retired	205	9
7	FW	Yes	27	No	10	146	6	Yes	5.8	Retired	126	6
8	FW	Yes	24	Yes	6	201	25	Yes	5.3	Retired	221	10
9	FW	Yes	32	No	15	450	3	Yes	8.6	Retired	60	4
10	FW	Yes	30	No	8	189	2	Yes	8.6	Retired	31	3
11	FW	Yes	29	No	7	230	4	Yes	4.5	Retired	30	2
12	FW	Yes	26	No	9	170	6	Yes	14.4	Retired	75	5
<b>13</b>	<b>FW</b>	<b>No</b>	<b>20</b>	<b>No</b>	<b>3</b>	<b>59</b>	<b>11</b>	<b>Yes</b>	<b>24.0</b>	<b>Active</b>	<b>31</b>	<b>5</b>
<b>13</b>	<b>FW</b>	<b>No</b>	<b>20</b>	<b>No</b>	<b>3</b>	<b>59</b>	<b>13</b>	<b>Yes</b>	<b>21.9</b>	<b>Active</b>	<b>31</b>	<b>5</b>
14	FW	Yes	30	No	11	314	15	Yes	8.8	Active	53	2
15	GK	No	20	No	2	0	3	Yes	5.9	Retired	0	1
16	MF	No	24	Yes	2	53	9	Yes	9.0	Retired	5	2
<b>17</b>	<b>MF</b>	<b>Yes</b>	<b>24</b>	<b>No</b>	<b>3</b>	<b>85</b>	<b>16</b>	<b>Yes</b>	<b>5.5</b>	<b>Retired</b>	<b>39</b>	<b>3</b>
<b>17</b>	<b>MF</b>	<b>Yes</b>	<b>25</b>	<b>No</b>	<b>4</b>	<b>97</b>	<b>26</b>	<b>Yes</b>	<b>1.9</b>	<b>Retired</b>	<b>27</b>	<b>2</b>
18	MF	Yes	28	No	13	158	3	Yes	7.6	Retired	13	2
19	MF	Yes <sup>b</sup>	19	No	1	0	7	Yes	23.0	Retired	54	5
20	MF	Yes	31	Yes	14	349	25	Yes	3.3	Retired	77	6
21	MF	Yes <sup>b</sup>	23	No	8	93	58	Yes	5.3	Active	167	7
22	MF	Yes <sup>b</sup>	25	No	5	129	13	Yes	5.4	Active	96	5
23	MF	No	24	No	5	56	3	Yes	13.1	Active	24	2
24	MF	Yes	32	No	11	182	15	No	—	Retired	0	3
Mean ± SD			25.0 ± 4.0		6.7 ± 4.3	141.0 ± 117.8	11.5 ± 12.3		9.2 ± 6.8		70.4 ± 70.9	4.3 ± 7.0

<sup>a</sup>Patients in boldface had bilateral surgery. DF, defender; FW, forward; GK, goalkeeper; MF, midfielder.

<sup>b</sup>Played for youth national team.

repair, or reconstruction), and location of the chondral defect (femoral or acetabular) and if it required microfracture.

Statistical Analysis

Statistical analyses were performed with SPSS 21.0 (IBM Corp). Univariate analysis was performed with the Student *t* test and Fisher exact test. Correlations were performed with Spearman rho analysis. All reported *P* values are 2-tailed, with a value <.05 indicating a statistically significant difference.

RESULTS

Thirty-two hips in 30 professional soccer players underwent hip arthroscopic surgery for FAI by a single surgeon. Six players who had not retired before arthroscopic surgery were excluded because they did not have contracts at the time of surgery. Three were waived before surgery and officially retired after arthroscopic surgery, and 3 were waived, left the team, or had their contracts declined before surgery and officially retired after arthroscopic surgery. All 6 retired just after surgery (≤3 months; mean [±SD], 1.6 ± 0.7 months). Finally, 24 soccer players were included in the study. Two players underwent bilateral arthroscopic surgery (8%); one player underwent surgery

on the opposite side 2 months after the prior surgery, and another player had a 10-month gap between surgeries, for a total of 26 hips.

Patient Characteristics

The demographics of 26 hips are shown in Table 1. Players by position included 9 strikers (forward, 38%), 9 midfielders (38%), 5 defenders (19%), and 1 goalkeeper (4%). For 16 of 26 hips (62%), the player had at least 1 match playing with the national team (5 from the national team of the United States; 2 from England, Scotland, and Sweden; and 1 from Chile, Germany, Jamaica, Nigeria, and Slovenia), and 3 (12%) had played for youth, under-20, or under-23 categories of their national team (the “under” category included 2 from the national team of England and 1 from France). Twelve players were right-side dominant, 9 were left-side dominant, and 3 did not have dominant sides. Twelve (46%) hip arthroscopic procedures were performed on the dominant side and 11 on the nondominant side. Four hips had symptoms for >2 years before arthroscopic surgery, while 15 hips had symptoms for <1 year.

Four players had undergone hip arthroscopic procedures before undergoing arthroscopic surgery by the senior author. All previous surgeries were performed at other institutions. One player underwent labral debridement 6

TABLE 2  
Hip Radiographic Measurements

	Mean $\pm$ SD or n (%)
Lateral center edge angle, deg	32.9 $\pm$ 6.4
$\leq 25^\circ$	2 (8)
Sharp angle, deg	39.0 $\pm$ 7.2
Weighthbearing surface angle, deg	7.9 $\pm$ 5.5
Lateral joint space, mm	4.2 $\pm$ 1.1
Anterior joint space, mm	4.1 $\pm$ 1.5
Foveal joint space, mm	4.6 $\pm$ 1.2
$\leq 2.0$ mm	0 (0)
Alpha angle, deg	67.5 $\pm$ 11.0
$\geq 55^\circ$	23 (88)

months before arthroscopic surgery. The second player underwent 2 previous arthroscopic procedures 15 and 18 months before arthroscopic surgery. The surgeries included chondroplasty and ossicle removal for impingement. The third player had undergone hip arthroscopic surgery 18 months prior. The surgery included labral debridement and a chondral defect of the femoral head that was not treated. At arthroscopic surgery for this study, the patient required labral reconstruction and microfracture of the femoral head. The fourth patient had undergone previous surgery 6 years prior, which included labral debridement. At arthroscopic surgery for this study, labral repair, cam resection, and lysis of adhesions were performed.

### Radiographic Evaluation

The radiographic measurements are shown in Table 2.

### Intraoperative Findings and Treatments

There were 4 revisions and 22 primary hip arthroscopic procedures. The arthroscopic findings and treatments performed are presented in Table 3.

Players who had severe cartilage damage were significantly older than those without severe cartilage damage (mean age, 28.0 years vs 22.9 years, respectively;  $P < .001$ ) (Table 4).

### Return to Professional Soccer Activity

One player required revision surgery because of heterotopic ossification and adhesions 5 months after initial arthroscopic surgery. He returned to play at 9 months after revision arthroscopic surgery (Figure 1).

Of the 24 players (26 hips), 23 players (25 hips) returned to play at the professional level (96%), including the 1 patient who required revision surgery. The mean time between surgery and the first professional game played was 9.2 months (range, 1.9-24.0 months). Patients with  $<12$  months of symptoms before arthroscopic surgery returned at a mean of 11 months, while patients with  $\geq 12$  months of symptoms before arthroscopic surgery returned at 7 months ( $P = .16$ ). Seven players (8 hips) were still playing professionally at the end of 2016. The

TABLE 3  
Intraoperative Findings and Treatments

	n (%) or Mean $\pm$ SD
Labral tear	26 (100)
Length of labral tear, mm	35.3 $\pm$ 10.3
Focal cartilage damage: acetabulum	
Outerbridge grade 0-2	18 (69)
Outerbridge grade 3-4	8 (31)
Size of grade 3-4 lesions microfractured, mm <sup>2</sup>	94.8 $\pm$ 40.5
Focal cartilage damage: femoral head	
Outerbridge grade 0-2	20 (77)
Outerbridge grade 3-4	6 (23)
Size of grade 3-4 lesions microfractured, mm <sup>2</sup>	120.8 $\pm$ 82.5
Labral repair	19 (73)
Labral reconstruction	7 (27)
Microfracture	
Acetabulum	5 (19)
Femoral head	2 (8)

mean number of games after surgery was 70, and the mean length of career after surgery was 4.3 years (calculation at the end of 2016, including active players).

### National Team Experience and Return to Play

In this series, there were 15 players (16 hips) that had national team experience (not including the "under" category national team). A comparison between players who had national team experience and those who did not is presented in Table 5. National team players returned to play significantly earlier than those without national team experience (mean, 6.6 months vs 14.1 months, respectively;  $P = .018$ ).

Earlier return to the professional game was also significantly related to the number of games played before surgery. The number of appearances before surgery ( $r = -0.56$ ,  $P = .004$ ) (Figure 2), preoperative career length ( $r = -0.45$ ,  $P = .026$ ), and age at surgery ( $r = -0.49$ ,  $P = .013$ ) were negatively correlated with the time between surgery and the first appearance after surgery. Players who had more than 60 games' experience before surgery (17 hips) were able to return in a mean of 6.2 months, and this was significantly earlier than those who had less than 60 appearances before surgery (9 hips; mean, 15.8 months;  $P = .004$ ).

### DISCUSSION

The main finding of this study was that 96% of professional soccer players were able to return to play professionally after undergoing arthroscopic hip surgery for symptomatic FAI and labral injuries. The mean time between surgery and the first professional game played was 9.2 months (range, 1.9-24.0 months). Players with national team experience, in spite of their older age, were able to return to play earlier than those without national team experience.

Hip arthroscopic procedures have increased exponentially during the past 2 decades probably because of the

TABLE 4  
Severe Cartilage Damage (Outerbridge Grade 3 or 4) and Microfracture<sup>a</sup>

	Severe Cartilage Damage			Microfracture		
	No	Yes	P Value	No	Yes	P Value
No. of hips	15	11		20	6	
Age, y	22.9	28.0	<.001	23.8	29.2	.002
No. of games before surgery	89	211	.006	106	256	.004
Career before surgery, y	4.7	9.3	.006	5.5	10.5	.011
Returned to play professional games, %	100	91	.423	100	83	.231
Time between surgery and first game, mo	11.6	6.7	.043	10.3	7.0	.087
No. of games after surgery <sup>b</sup>	75	70	.870	73	75	.941
Career after surgery, <sup>b</sup> y	4.7	3.9	.484	4.5	4.0	.733

<sup>a</sup>Data are the mean unless otherwise indicated. P values are calculated from the Student t test.

<sup>b</sup>Players who are still active are included.

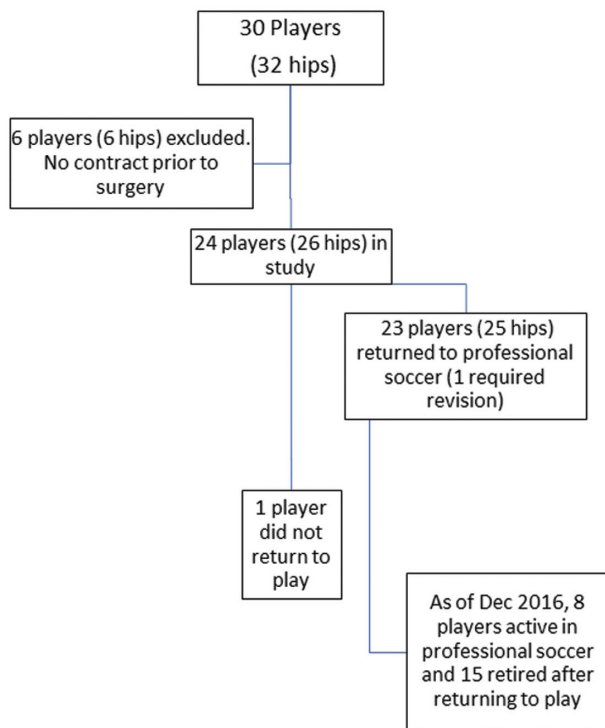


Figure 1. Flowchart of the sample.

better understanding of hip-related disorders and improved surgical techniques. Concomitantly, the indication for this procedure has expanded to high-level athletes, which requires returning to their previous activity level to consider a procedure “successful.” Byrd and Jones<sup>3</sup> reported on 200 athletes (10 of whom were professional/intercollegiate soccer players) who underwent the arthroscopic treatment of FAI and reported that 181 athletes (90%) returned to their previous level of competition, with 95% returning at the professional level and 85% at the collegiate level. While only a small number of patients in that study were soccer players, the return-to-play rate was similar. However, we are unable to determine the

TABLE 5  
National Team Experience and Return to Play<sup>a</sup>

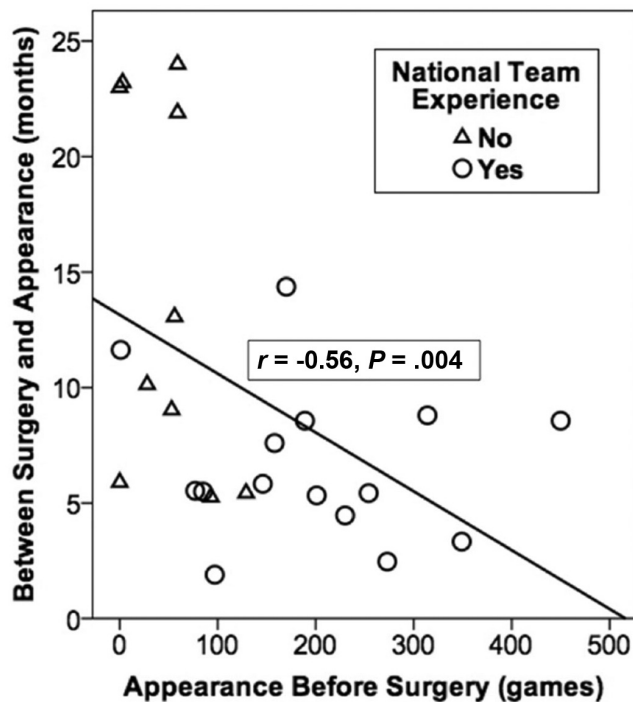
	National Team Experience		P Value
	Yes	No	
No. of hips	16	10	
Age, y	27.1	21.7	<.001
No. of games before surgery	199	48	<.001
Career before surgery, y	8.6	3.5	.002
Severe cartilage damage, %	56	20	.109
Microfracture, %	38	0	.053
Returned to play professional games, %	94	100	>.999
Time between surgery and first game, mo	6.6	14.1	.018
No. of games after surgery <sup>b</sup>	80	64	.597
Career after surgery, <sup>b</sup> y	4.2	4.7	.680

<sup>a</sup>Data are the mean unless otherwise indicated.

<sup>b</sup>Players who are still active are included.

exact rate for soccer players. A systematic review performed by Alradwan et al<sup>2</sup> demonstrated that 92% of the athletes treated for FAI were able to return to activity, across a variety of sports and levels of play, and that 88% of athletes returned to preinjury activity levels of participation. However, not all athletes in the study were high level. The authors reported that the studies analyzed were of high quality, despite minor methodological limitations. Similarly, a recent systematic review of 18 articles demonstrated that 87% of the athletes were able to return to their sports.<sup>5</sup> The present study reported a 96% rate of return to professional play in soccer players, similar to the previously reported rates for professional players from other sports.

In the present study, the mean time between surgery and the first professional soccer game played was 9.2 months (range, 1.9-24.0 months). These results are similar to previous studies.<sup>6,10,13</sup> A study that included professional, college, high school, and club baseball players reported a mean of 8.6 ± 4.2 months to return to play after



**Figure 2.** Negative relationship between appearance before surgery and return to play.

FAI surgery and labral repair.<sup>6</sup> Levy et al<sup>10</sup> reported a return to running after hip arthroscopic surgery for FAI and capsular plication at a mean of  $8.5 \pm 4.2$  months in 48 patients including recreational and professional runners. While players return to sports at various times because of the different seasons and breaks between seasons, 8 to 9 months after arthroscopic surgery or the following season is commonly the average time to return to play.<sup>6,10,13</sup>

When the players in the current study were separated into 2 groups based on whether they had previous national team experience, players who played for the national team were significantly older at surgery ( $P = .004$ ) and more experienced ( $P = .005$ ). However, these national team players returned to the game after surgery significantly earlier than non-national team members ( $P = .018$ ). Participation on the national team increases the number of games that players are able to play, explaining the higher number of games played before surgery. These high-level players may also experience significant socioeconomic pressures from trainers, teams, managers, and sponsors for an early return to competition.<sup>17,20</sup> This was also seen in players with more soccer experience before arthroscopic surgery. More experienced players returned sooner, which may be because of higher levels of play or more experience in dealing with injuries and rehabilitation.

Chondral lesions can be particularly debilitating injuries for an athlete. Casartelli et al<sup>5</sup> suggested in a systematic review that diffuse hip osteoarthritis at the time of surgery was a risk factor that would not allow athletes to return to sport. Another study evaluating return to play in elite athletes showed no detectable statistically significant difference

between return-to-play rates after hip arthroscopic surgery between patients undergoing microfracture or hip arthroscopic surgery without microfracture.<sup>12</sup> The current study showed no statistically significant differences in return to play when severe chondral damage was found or microfracture was performed. However, no player had diffuse osteoarthritis.

This study is not without limitations. First, the relatively small sample of patients might have underpowered our results. We excluded 6 patients because they were not under contract at the time of arthroscopic surgery. It is unclear why they waited until shortly after surgery to retire; however, this may be because of compensation or insurance issues. Second, the lack of objective and patient-reported outcomes is also a limitation. However, for these patients, the most important outcome was returning to play soccer at the professional level, so this was the focus of this study. In addition, parts of data regarding the times and causes for returning/not returning to sports were retrieved from various websites, which could have introduced bias to the results. Finally, the time from surgery to the first professional game can be biased for external reasons not related to surgery and recovery, as the season and off-season periods in their leagues and countries and factors related to skills and game rhythms did not allow the players to fit on the team at the time of their full recovery. Therefore, the first game played may not reflect the real moment when they were capable to return to play.

In conclusion, the arthroscopic management of FAI in symptomatic professional soccer players allowed them to return to the same skill level before surgery in 96% of the cases. Players with national team experience, despite their older age, returned to play earlier than those without national team experience.

## REFERENCES

1. Agricola R, Bessems JH, Ginai AZ, et al. The development of cam-type deformity in adolescent and young male soccer players. *Am J Sports Med.* 2012;40(5):1099-1106
2. Alradwan H, Philippon MJ, Farrokhyar F, et al. Return to preinjury activity levels after surgical management of femoroacetabular impingement in athletes. *Arthroscopy.* 2012;28(10):1567-1576.
3. Byrd JW, Jones KS. Arthroscopic management of femoroacetabular impingement in athletes. *Am J Sports Med.* 2011;39:7S-13S.
4. Byrd JW, Jones KS. Hip arthroscopy in athletes: 10-year follow-up. *Am J Sports Med.* 2009;37(11):2140-2143.
5. Casartelli NC, Leunig M, Maffioletti NA, Bizzini M. Return to sport after hip surgery for femoroacetabular impingement: a systematic review. *Br J Sports Med.* 2015;49(12):819-824.
6. Degen RM, Fields KG, Wentzel CS, et al. Return-to-play rates following arthroscopic treatment of femoroacetabular impingement in competitive baseball players. *Phys Sportsmed.* 2016;44(4):385-390.
7. Fuller CW, Ekstrand J, Junge A, et al. Consensus statement on injury definitions and data collection procedures in studies of football (soccer) injuries. *Scand J Med Sci Sports.* 2006;16(2):83-92.
8. Gerhardt MB, Romero AA, Silvers HJ, Harris DJ, Watanabe D, Mandelbaum BR. The prevalence of radiographic hip abnormalities in elite soccer players. *Am J Sports Med.* 2012;40(3):584-588.
9. Geyer MR, Philippon MJ, Fagrelis TS, Briggs KK. Acetabular labral reconstruction with an iliotibial band autograft: outcome and survivorship analysis at minimum 3-year follow-up. *Am J Sports Med.* 2013;41(8):1750-1756.

10. Levy DM, Kuhns BD, Frank RM, et al. High rate of return to running for athletes after hip arthroscopy for the treatment of femoroacetabular impingement and capsular plication. *Am J Sports Med.* 2017;45(1):127-134.
11. McCarthy J, Barsoum W, Puri L, Lee J-A, Murphy S, Cooke P. The role of hip arthroscopy in the elite athlete. *Clin Orthop Relat Res.* 2003;406(1):71-74.
12. McDonald JE, Herzog MM, Philippon MJ. Return to play after hip arthroscopy with microfracture in elite athletes. *Arthroscopy.* 2013;29(2):330-335.
13. Menge TJ, Bhatia S, McNamara SC, Briggs KK, Philippon MJ. Femoroacetabular impingement in professional football players: return to play and predictors of career length after hip arthroscopy. *Am J Sports Med.* 2017;45(8):1740-1744.
14. Menge TJ, Briggs KK, Philippon MJ. Predictors of length of career after hip arthroscopy for femoroacetabular impingement in professional hockey players. *Am J Sports Med.* 2016;44(9):2286-2291.
15. Molloy MG, Molloy CB. Contact sport and osteoarthritis. *Br J Sports Med.* 2011;45(4):275-277.
16. Mölsä J, Airaksinen O, Näsman O, Torstila I. Ice hockey injuries in Finland: a prospective epidemiologic study. *Am J Sports Med.* 1997;25(4):495-499.
17. Nho SJ, Magennis EM, Singh CK, Kelly BT. Outcomes after the arthroscopic treatment of femoroacetabular impingement in a mixed group of high-level athletes. *Am J Sports Med.* 2011;39(suppl 1): 14S-19S.
18. Parvizi J, Leunig M, Ganz R. Femoroacetabular impingement. *J Am Acad Orthop Surg.* 2007;15(9):561-570.
19. Pfirrmann D, Herbst M, Ingelfinger P, Simon P, Tug S. Analysis of injury incidences in male professional adult and elite youth soccer players: a systematic review. *J Athl Train.* 2016;51(5):410-424.
20. Philippon M, Schenker M, Briggs K, Kuppersmith D. Femoroacetabular impingement in 45 professional athletes: associated pathologies and return to sport following arthroscopic decompression. *Knee Surg Sports Traumatol Arthrosc.* 2007;15(7):908-914.
21. Philippon MJ, Ho CP, Briggs KK, Stull J, LaPrade RF. Prevalence of increased alpha angles as a measure of cam-type femoroacetabular impingement in youth ice hockey players. *Am J Sports Med.* 2013;41(6):1357-1362.
22. Philippon MJ, Stubbs AJ, Schenker ML, Maxwell RB, Ganz R, Leunig M. Arthroscopic management of femoroacetabular impingement osteoplasty technique and literature review. *Am J Sports Med.* 2007;35(9):1571-1580.
23. Tak I, Glasgow P, Langhout R, Weir A, Kerkhoffs G. Hip range of motion is lower in professional soccer players with hip and groin symptoms or previous injuries, independent of cam deformities. *Am J Sports Med.* 2016;44(3):682-688.
24. Willimon SC, Briggs KK, Philippon MJ. Intra-articular adhesions following hip arthroscopy: a risk factor analysis. *Knee Surg Sports Traumatol Arthrosc.* 2014;22(4):822-825.
25. Wong P, Hong Y. Soccer injury in the lower extremities. *Br J Sports Med.* 2005;39(8):473-482.