

Type II Medial Meniscus Root Repair With Peripheral Release for Addressing Meniscal Extrusion



Nicholas N. DePhillipo, M.S., A.T.C., O.T.C., Mitchell I. Kennedy, B.S.,
Jorge Chahla, M.D., Ph.D., and Robert F. LaPrade, M.D., Ph.D.

Abstract: Medial meniscal root tears are often disabling injuries that can occur in isolation during low-velocity, deep knee flexion maneuvers in middle-aged patients. The most common meniscal root tear pattern is a radial tear near the root attachment (type II). Root tears are often associated with meniscal extrusion, identified on magnetic resonance imaging. Relocation of the meniscal root to its anatomic center is a reported current difficulty faced by surgeons during surgical repair. However, this can be achieved via sufficient peripheral release of the posteromedial capsular attachment of the medial meniscus. The purpose of this Technical Note is to describe the authors' current surgical technique for medial meniscus root repair with a peripheral release for addressing meniscal extrusion. Classifications: level I (knee); level II (meniscus).

Medial meniscal root tears are often disabling injuries that can occur in isolation during low-velocity, deep knee flexion maneuvers in middle-aged patients.¹ Most patients present with joint swelling and complaints of medial joint line pain, exacerbated with deep knee flexion on examination. The most common medial meniscal root tear pattern is a radial tear near the root attachment (type II).^{2,3} Root tears are often associated with meniscal extrusion, identified on the coronal view of magnetic resonance imaging (MRI), measured at the level of the superficial medial collateral ligament (SMCL).⁴

Previous evidence has shown that meniscal root tears may progress to end-stage osteoarthritis within 1 to 2 years if not addressed surgically.⁵⁻⁸ However, relocation of the meniscal root to its anatomic center

is a reported current difficulty faced by surgeons during surgical repair. This anatomic relocation can be achieved via sufficient peripheral release of the posteromedial capsular attachment of the medial meniscus at the time of surgery. The purpose of this Technical Note is to describe the authors' current surgical technique for a medial meniscus root repair with peripheral release for addressing meniscal extrusion.

Surgical Technique

A detailed video of the technique is shown in [Video 1](#). Pearls and pitfalls of this technique and the advantages and disadvantages for this approach are described in [Tables 1](#) and [2](#), respectively.

Indications and Contraindications

Indications for type II medial meniscus root repair are clinical and radiographic evidence of a radial tear within 0 to 9 mm from the medial meniscus root attachment, confirmed during arthroscopy.⁹ The characteristic "ghost sign," indicated by a sudden disappearance of a well-defined meniscal structure, can occasionally be visualized in sagittal plane MRIs.¹⁰ Contraindications for meniscal root repair surgery are Kellgren-Lawrence grade 3 to 4, diffuse grade 3 to 4 chondromalacia of the ipsilateral compartment, or a patient deemed unable to meet the postoperative rehabilitation protocol requirement of being non-weightbearing for 6 weeks. Plain radiographs including long-standing alignment films and

From the Steadman Philippon Research Institute (M.I.K.); The Steadman Clinic (N.N.D., R.F.L.), Vail, Colorado, U.S.A.; and Midwest Orthopaedics at Rush (J.C.), Chicago, Illinois, U.S.A.

The authors report the following potential conflicts of interest or sources of funding: R.F.L. is a consultant and receives royalties from Smith & Nephew, Arthrex, and OSSUR. Full ICMJE author disclosure forms are available for this article online, as [supplementary material](#).

Received March 6, 2019; accepted May 1, 2019.

Address correspondence to Robert F. LaPrade, M.D., Ph.D., Twin Cities Orthopedics, 4010 West 65th Street, Edina, MN 55345, U.S.A. E-mail: laprademdphd@gmail.com

© 2019 by the Arthroscopy Association of North America. Published by Elsevier. This is an open access article under the CC BY-NC-ND license (<http://creativecommons.org/licenses/by-nc-nd/4.0/>).

2212-6287/19300

<https://doi.org/10.1016/j.eats.2019.05.001>

Table 1. Pearls and Pitfalls

Pearls	Pitfalls
Identification and preparation of the anatomic attachment site of the medial meniscus posterior root is essential in reestablishing the anatomic position and subsequent biomechanical restoration of the root.	Offset of the medial meniscus from its position within the joint, resulting from extrusion, results in disproportionate distribution of loads within the medial compartment, leading to progression of osteoarthritis.
A grasper is used with the medial meniscus to assess relative mobility for returning the root of the posterior meniscus to its anatomic insertion.	During root repair, extensive capsular attachments to the meniscus can restrain the ability of the meniscal root to be pulled back into the joint, potentially leading to inadequate positioning or inadequate restoration of load distribution.
Significantly extruded menisci require sectioning of fibrous joint capsule attachments to the meniscal body with a rotary scissors, improving mobility of the meniscus for easier return inside the joint.	Avoid tying sutures directly over the tibia, as the bone can cut the sutures and cause laxity in the root repair fixation.
The meniscal rim should be repositioned to its anatomic attachment with in situ fixation for root tears located medially to the medial meniscal root attachment.	
Tie the root repair over a button to allow for secure fixation and postoperative visualization of the root repair.	

Rosenberg views are included in addition to the normal x-ray series to ensure that a patient does not have significant unwanted genu varum malalignment or decreased tibiofemoral joint space.³

Patient Positioning and Anesthesia

The patient is placed in the supine position on the operating table. After the induction of general anesthesia, a bilateral knee examination is performed to evaluate for any concurrent ligamentous instability and to assess for knee range of motion. A well-padded high-thigh tourniquet is subsequently placed on the operative leg, which is then placed into a leg holder (Mizuho OSI, Union City, CA), while the contralateral knee is placed into an abduction stirrup (Birkova Products, Gothenburg, NE).

Surgical Approach

Standard anterolateral and anteromedial portals are made adjacent to the patellar tendon. The joint is insufflated with normal saline and visualized with a 30° arthroscopic camera (Smith & Nephew, Andover, MA). An arthroscopic shaver (Smith & Nephew) is inserted into the knee, and any notable adhesions are

removed. When the root tear is located medial to the true medial posterior root attachment (Fig 1), restoring the meniscal rim with in situ fixation aids in better anatomic restoration than attempting to reduce the meniscus to a nonanatomic position.¹¹ The location of the planned root repair on the tibial plateau should then be decorticated using a curved curette or curved shaver (Fig 2). When the medial meniscus is found to have significant extrusion (Fig 3), it is important to perform sufficient release of the meniscus from the posterior and posteromedial joint capsule so that the meniscus body can be pulled back inside the joint when the root repair is tied down to the decorticated portion of the tibial plateau. This release can be performed with rotary scissors (Acuflex; Smith & Nephew), cutting along the posterior

Table 2. Advantages and Disadvantages

Advantages	Disadvantages
Improves mobility for pulling the meniscus back within the knee joint	Extensive debridement of the capsular attachments may result in inadequate peripheral healing
Reduces difficulty from attempting to tension the posterior meniscal attachment to its anatomic attachment site	Technically challenging

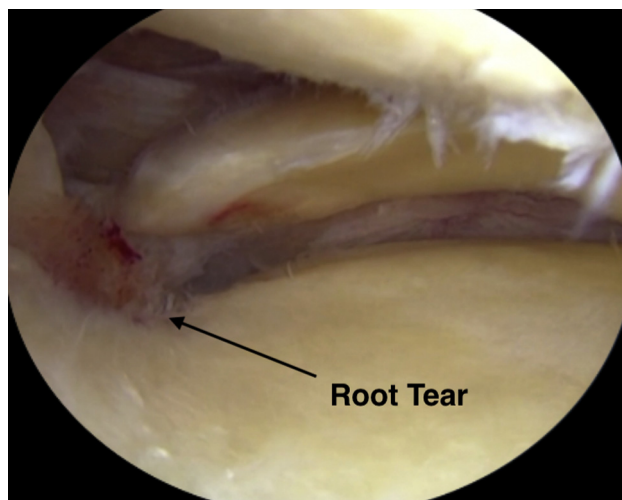


Fig 1. Arthroscopic view in a right knee, identifying a posterior medial meniscal root tear.

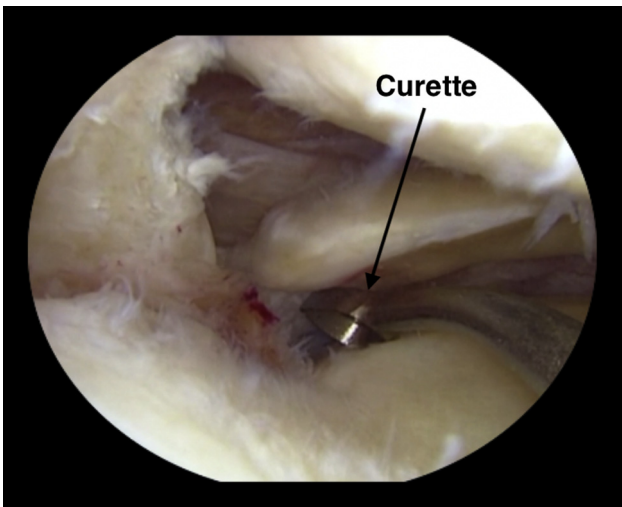


Fig 2. Arthroscopic view in a right knee, showing preparation of the native root attachment by decortication of the attachment site using a curved curette.

meniscocapsular junction both inferiorly and superiorly while leaving the midbody meniscal capsular attachments intact (Fig 4). A grasper should be used to assess the adequacy of the release of the extruded meniscal root and determine when the peripheral release is sufficient. In addition, pie-crusting of the meniscofemoral attachment of the sMCL can be performed to allow for increased visualization and opening of the medial compartment for improved root repair access and to avoid iatrogenic damage to the medial femoral condyle joint surfaces.

Transtibial Tunnels

An initial incision for the transtibial tunnels is made just medial to the tibial tubercle ~5 cm distal to the joint line. To best restore the footprint of the repair and increase the chance of biologic healing, 2 transtibial

tunnels are created at the location of the root attachment. A tibial tunnel guide (Smith & Nephew) is then used to ream the first 2.4-mm tunnel (along the posterior aspect of the posterior root attachment site). This system has a 2.4-mm cannula that stays in place while the drill pin is removed. The second tunnel is placed anteriorly 5 mm using an offset guide (Smith & Nephew). The tunnels are visualized arthroscopically to verify correct tunnel placement, and the drill pins are removed, leaving the 2 cannulas in place for passing the sutures (Fig 5).

Suture Passing

A suture-passing device (Mini-FirstPass; Smith & Nephew) is used to pass a suture tape through the far posterior portion of the detached meniscal root (Fig 6), ~5 mm medial to its lateral edge for the medial meniscus, passing from the tibial to the femoral side. The suture-retrieving mechanism pulls out the suture tape through the anteromedial portal (through a cannula, to avoid soft tissue bridges) as the device is removed. Before passing the second suture tape through the meniscus, the first suture tape is shuttled down through the more posteriorly placed tibial tunnel to avoid intra-articular suture tangling. To accomplish this, a looped nylon passing suture is placed up the posterior tunnel cannula, and the posterior suture is shuttled down the posterior tunnel. The steps are repeated with the second suture tape positioned through the midportion of the meniscal root, anterior to the first suture tape placed into the meniscus. The second suture is then pulled down through the anterior positioned tibial cannula.

Root Fixation

The suture tapes are tied down over a cortical fixation device (Endobutton, Smith & Nephew) on the anteromedial tibia for the medial meniscal root repair (Fig 7),

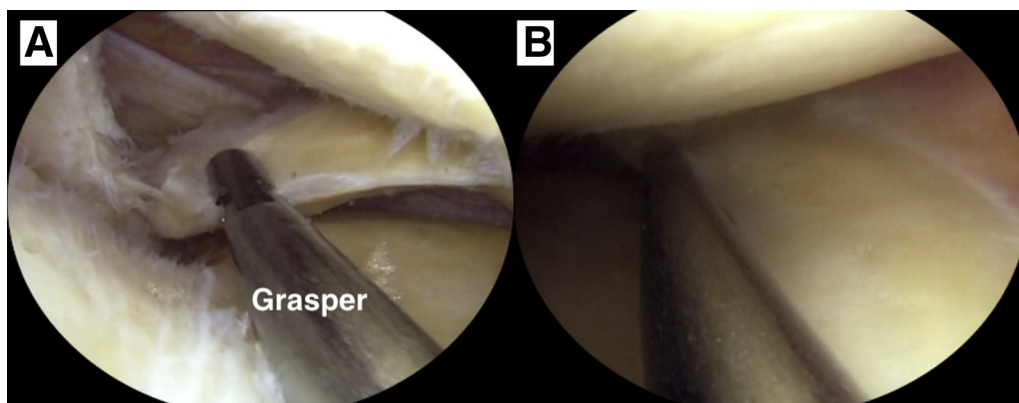


Fig 3. Arthroscopic view in a right knee, showing meniscal extrusion and an inability to pull the posterior (A) and medial aspect (B) of the meniscus, bringing the root to its native attachment site.

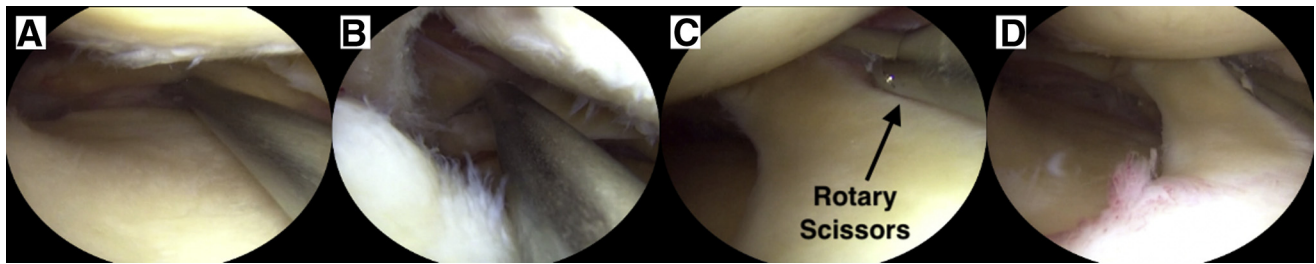


Fig 4. Arthroscopic view in a right knee, showing the lateral release performed with rotary scissors cutting along the posterior meniscocapsular junction both inferiorly (A) and superiorly (B) and release of the medial meniscocapsular junction superiorly (C), extending to the posterior region (D).

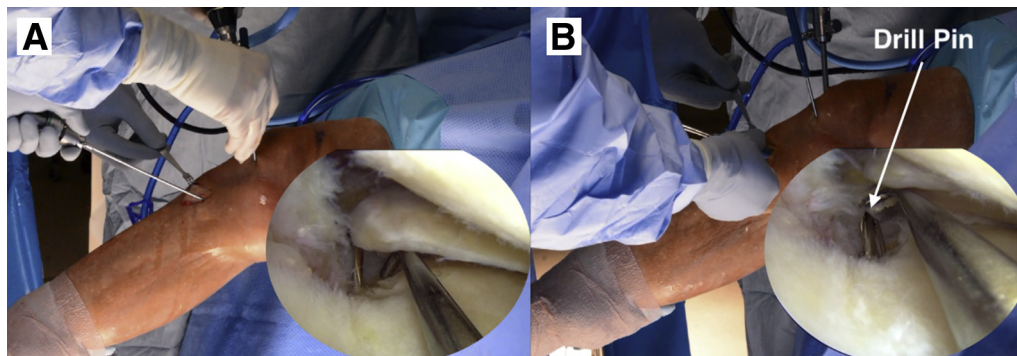


Fig 5. Anteromedial and arthroscopic views in a right knee, showing the 2 transtibial tunnels created at the native root attachment site, with the first tunnel created using a tibial tunnel guide (A) and the second tunnel separated by 5 mm using an offset guide (B).

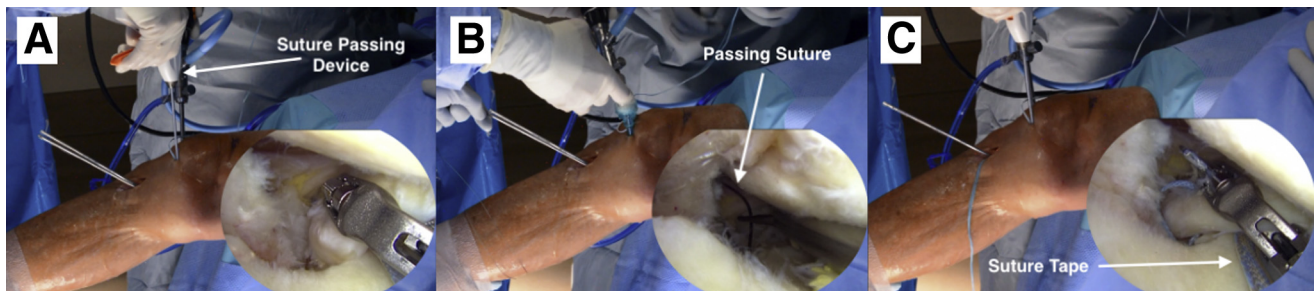


Fig 6. Anteromedial and arthroscopic views in a right knee, displaying the passing of a suture tape through the far posterior portion of the detached meniscal root (A), a suture-retrieving mechanism pulling out the suture tape through the anteromedial portal (B), and shuttling of the suture tape through the posterior tibial tunnel. These steps are repeated with the second suture tape positioned through the midportion of the meniscal root (C), anterior to the first suture tape placed into the meniscus.

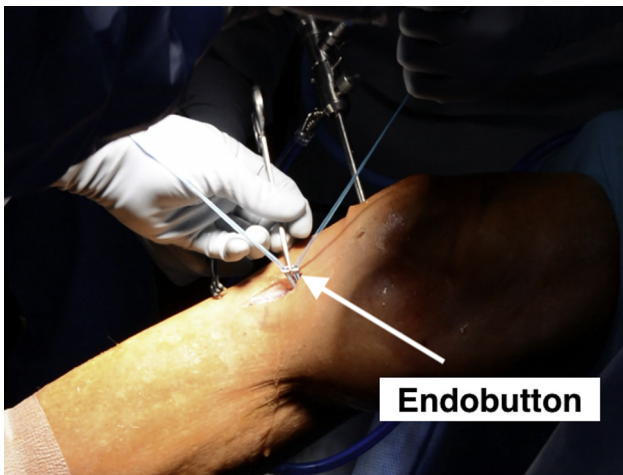


Fig 7. Anteromedial view in a right knee, showing the medial meniscal root repair fixation tying the suture tapes down over a cortical fixation device (Endobutton, Smith & Nephew) on the anteromedial tibia.

while the posterior root of the respective meniscus is visualized arthroscopically to confirm a secure repair (Fig 8).

Postoperative Protocol

After the procedure, the patient is to remain non-weightbearing for 6 weeks on crutches. Physical therapy begins on postoperative day 1 with a focus on pain control, reducing edema, and knee motion. Knee range of motion is limited from 0° to 90° for the first 2 weeks to protect the meniscal root repair, and then motion is progressed as tolerated. The patient is placed into a knee immobilizer during the entire non-weightbearing period of 6 weeks.

Weightbearing is initiated at 6 weeks postoperatively along with low-resistance cycling on a stationary bicycle. If a patient is in genu varum alignment, a medial unloader brace (Ossur Americas, Foothill Ranch, CA) is used once weightbearing

begins until a minimum of 4 months postoperatively, to allow for adequate healing and unloading of the root repair. Once patients can tolerate 20 minutes of walking with a nonantalgic gait pattern, a periodized strength program may be initiated that focuses on the sequential development of muscular endurance, strength, and power. Knee flexion during weight-bearing exercise is limited to 70° until 16 weeks postoperatively, to avoid excessive strain on the meniscal root repair.

Patients may begin a gradual return to activity progression ~5 months postoperatively. Clearance for return to all activities is determined after passing a functional sports test and clinical examination with plain radiographs at 6 to 7 months postoperatively.^{3,12}

Discussion

Restoration of the anatomic footprint of the posterior medial meniscal root attachment is essential for successful outcomes after a meniscal root repair. This technique describes the necessary approach of sufficiently releasing the extruded meniscus from adhesions and the posteromedial capsule to reduce the medial meniscus back into the joint. Additionally, pie-crusting of the femoral attachment of the sMCL may allow for increased visualization and opening of the medial compartment for improved root repair access, which has been previously reported to not affect valgus laxity or clinical outcomes.¹³

A nonanatomic posterior medial root repair has been shown previously to be insufficient at restoring knee biomechanics.¹¹ Specifically, a nonanatomic repair reduced contact area (35% to 53%), increased mean contact pressure (67%), and increased peak contact forces (59%) compared with intact meniscus. In contrast, when the posterior medial meniscus root was adequately released and restored to its native footprint, an anatomic repair increased contact area (average 17% to 36%), reduced mean contact pressure (−54%),

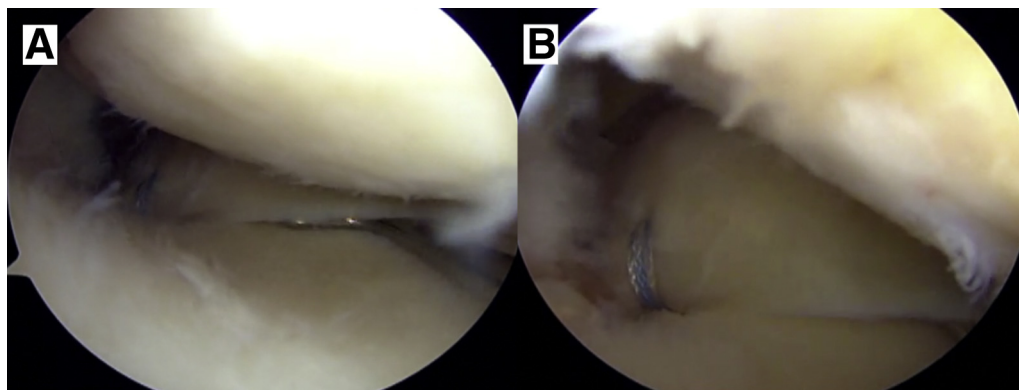


Fig 8. Arthroscopic view in a right knee, with probing of the posterior aspect of the meniscal body (A) and the root fixation (B), assuring the root fixation and the meniscus itself are secure.

and reduced peak contact forces (−33%) relative to intact meniscus.¹¹ These findings were the result of a nonanatomic root repair reattached 5 mm posteromedial to the native medial meniscus root attachment.¹¹

Similarly, Sekaran et al.¹⁴ reported that nonanatomic placement of a meniscal transplant 5 mm medial to the anatomic posterior medial meniscal attachment significantly increased the normalized maximum pressures over all flexion angles and shifted the centroid of contract area posteriorly. Starke et al.¹⁵ reported that nonanatomic placement of the root by 3 mm medially or laterally significantly affected the menisci's ability to convert tibiofemoral loads into circumferential tension, thereby compromising meniscal function.¹⁵ Therefore, in addition to performing a sufficient peripheral release, detailed knowledge of the native meniscal root attachment center and posterior medial capsule is necessary when performing root repair surgery.¹⁶⁻¹⁸

This Technical Note describes an expanded approach for anatomic restoration of medial meniscal posterior roots that are limited by mobility and inhibit restoring of the root to its necessary position, resolved by peripheral release of the posteromedial capsule and medial meniscus adhesions. Further clinical studies are needed to validate this technique, with patient follow-up to assess the effect from meniscal extrusion in long-term clinical scenarios.

References

1. Bhatia S, LaPrade CM, Ellman MB, LaPrade RF. Meniscal root tears: Significance, diagnosis, and treatment. *Am J Sports Med* 2014;42:3016-3030.
2. LaPrade CM, James EW, Cram TR, Feagin JA, Engebretsen L, LaPrade RF. Meniscal root tears: A classification system based on tear morphology. *Am J Sports Med* 2015;43:363-369.
3. LaPrade RF, Matheny LM, Moulton SG, James EW, Dean CS. Posterior meniscal root repairs: Outcomes of an anatomic transtibial pull-out technique. *Am J Sports Med* 2017;45:884-891.
4. LaPrade RF, Ho CP, James E, Crespo B, LaPrade CM, Matheny LM. Diagnostic accuracy of 3.0 T magnetic resonance imaging for the detection of meniscus posterior root pathology. *Knee Surg Sports Traumatol Arthrosc* 2015;23:152-157.
5. Cinque ME, Chahla J, Moatshe G, Faucett SC, Krych AJ, LaPrade RF. Meniscal root tears: A silent epidemic. *Br J Sports Med* 2018;52:872-876.
6. Faucett SC, Geisler BP, Chahla J, et al. Meniscus root repair vs meniscectomy or nonoperative management to prevent knee osteoarthritis after medial meniscus root tears: Clinical and economic effectiveness. *Am J Sports Med* 2018. 363546518755754.
7. Steineman BD, LaPrade RF, Santangelo KS, Warner BT, Goodrich LR, Haut Donahue TL. Early osteoarthritis after untreated anterior meniscal root tears: An in vivo animal study. *Orthop J Sports Med* 2017;5. 2325967117702452.
8. Krych AJ, Johnson NR, Mohan R, et al. Arthritis progression on serial MRIs following diagnosis of medial meniscal posterior horn root tear. *J Knee Surg* 2018;31: 698-704.
9. Padalecki JR, Jansson KS, Smith SD, et al. Biomechanical consequences of a complete radial tear adjacent to the medial meniscus posterior root attachment site: In situ pull-out repair restores derangement of joint mechanics. *Am J Sports Med* 2014;42:699-707.
10. Lee SY, Jee WH, Kim JM. Radial tear of the medial meniscal root: Reliability and accuracy of MRI for diagnosis. *Am J Roentgenol* 2008;191:81-85.
11. LaPrade CM, Foad A, Smith SD, et al. Biomechanical consequences of a nonanatomic posterior medial meniscal root repair. *Am J Sports Med* 2015;43:912-920.
12. Mueller BT, Moulton SG, O'Brien L, LaPrade RF. Rehabilitation following meniscal root repair: A clinical commentary. *J Orthop Sports Phys Ther* 2016;46: 104-113.
13. Jeon SW, Jung M, Chun YM, et al. The percutaneous piecrusting medial release during arthroscopic procedures of the medial meniscus does neither affect valgus laxity nor clinical outcome. *Knee Surg Sports Traumatol Arthrosc* 2018;26:2912-2919.
14. Sekaran SV, Hull ML, Howell SM. Nonanatomic location of the posterior horn of a medial meniscal autograft implanted in a cadaveric knee adversely affects the pressure distribution on the tibial plateau. *Am J Sports Med* 2002;30:74-82.
15. Starke C, Kopf S, Grobel KH, Becker R. The effect of a nonanatomic repair of the meniscal horn attachment on meniscal tension: A biomechanical study. *Arthroscopy* 2010;26:358-365.
16. Johannsen AM, Civitarese DM, Padalecki JR, Goldsmith MT, Wijdicks CA, LaPrade RF. Qualitative and quantitative anatomic analysis of the posterior root attachments of the medial and lateral menisci. *Am J Sports Med* 2012;40:2342-2347.
17. LaPrade CM, Ellman MB, Rasmussen MT, et al. Anatomy of the anterior root attachments of the medial and lateral menisci: A quantitative analysis. *Am J Sports Med* 2014;42: 2386-2392.
18. DePhillipo NN, Moatshe G, Chahla J, et al. Quantitative and qualitative assessment of the posterior medial meniscus anatomy: Defining meniscal ramp lesions. *Am J Sports Med* 2018. 363546518814258.