

Technical Note

Trochlear Osteochondral Shell Allograft Technique to Treat Trochlear Dysplasia in the Setting of Chondral Damage and Chronic Patellar Instability

Benjamin Kerzner, B.S., Safa Gursoy, M.D., Ph.D., Suhas P. Dasari, M.D.,
Luc M. Fortier, B.A., Adam B. Yanke, M.D., Ph.D., and Jorge Chahla, M.D., Ph.D.

Abstract: Chronic patellar instability is characterized by recurrent dislocation events due to anatomical distortions as well as insufficiency of surrounding stabilizing structures, ultimately impacting patients' quality of life. In the setting of recurrent instability, patella alta, and trochlear dysplasia, there is also increased likelihood of symptomatic chondral damage in these patients. In this Technical Note, we describe the management of a patient with chronic lateral patellar instability, pain outside of dislocation events, and extensive surgical history to the knee. The surgical management included a combined approach, using a shell osteochondral allograft transplant to the trochlea, cylindrical osteochondral allograft transplantation to the patella, and revision tibial tubercle osteotomy with medial patellofemoral ligament reconstruction.

Chronic patellar instability is commonly associated with underlying trochlear dysplasia, an increased Q angle, insufficiencies of medial stabilizing structures, as well as increased tibial tubercle-to-trochlear groove (TT-TG) distance.^{1,2} In a patient with chronic patellar instability presenting with a significant J sign, there are issues with patellar tracking. The patella is normally

maintained within the groove during flexion and extension of the knee by the combination of a lateral trochlea, a deep sulcus, and medial patellofemoral ligament (MPFL) integrity.³

Reconstruction of the MPFL has been reported in the literature as a means of addressing chronic patellar instability and improving outcome scores while also decreasing redislocation/instability events.⁴ Cregar et al.⁵ performed a systematic review to evaluate risk factors associated with MPFL reconstruction failure in 1,287 knees and found that more severe trochlear dysplasia (types C and D) as well as femoral tunnel malposition had the most consistent association with greater rates of redislocations and inferior patient-reported outcomes. In addition, TT-TG distance has been shown, regardless of training level, to confirm the degree of lateralization of the tibial tubercle in those with patellofemoral instability.⁶ The combination of a MPFL procedure with an additional distal realignment procedure, such a tibial tubercle osteotomy (TTO), may be warranted to address the clinical dislocation events and the radiographic findings of increased TT-TG distance.⁷

There are select cases of chronic patellar instability in which the use of a trochleoplasty procedure in combination with a variety of other procedures is warranted, including MPFL reconstruction.^{8,9} The benefit of trochleoplasty is that it addresses high-grade trochlear dysplasia (Dejour B and D dysplastic trochleas) with patellar instability in patients without patellofemoral

From Midwest Orthopaedics at Rush (B.K., S.G., S.P.D., L.M.F., A.B.Y., J.C.) and Department of Orthopaedic Surgery, Rush University Medical Center (A.B.Y., J.C.), Chicago, Illinois, U.S.A.

The authors report the following potential conflicts of interest or sources of funding: A.B.Y. reports other from AlloSource, outside the submitted work; paid consultant for AlloSource, CONMED Linvatec, JRF Ortho, and Olympus; unpaid consultant for Patient IQ, Smith & Nephew, and Sparta Biomedical; research support for Arthrex, Organogenesis, and Vericel; and stock or stock options for Patient IQ. J.C. reports and paid consultant for Arthrex, CONMED Linvatec, Ossur, and Smith & Nephew; and board member/committee appointments: American Orthopaedic Society for Sports Medicine, Arthroscopy Association of North America, and International Society of Arthroscopy, Knee Surgery, and Orthopaedic Sports Medicine. Full ICMJE author disclosure forms are available for this article online, as [supplementary material](#).

Received September 9, 2021; accepted October 19, 2021.

Address correspondence to Jorge Chahla, M.D., Ph.D., Department of Orthopaedic Surgery, Rush University Medical Center, 1611 W Harrison St., Suite 300, Chicago, IL 60612. E-mail: Jorge.Chahla@rushortho.com

© 2021 THE AUTHORS. Published by Elsevier Inc. on behalf of the Arthroscopy Association of North America. This is an open access article under the CC BY-NC-ND license (<http://creativecommons.org/licenses/by-nc-nd/4.0/>).

2212-6287/211291

<https://doi.org/10.1016/j.eats.2021.10.014>

arthritis.¹⁰ Trochleoplasty additionally helps to improve the transition of the patella into the groove and provides an osseous restraint in degrees of flexion where the MPFL has increased laxity due to its anisometric nature. Patients with significant evidence of patellofemoral osteoarthritis and associated pain may be contraindicated for a trochleoplasty with or without concomitant procedures.

Chondral lesions and concomitant instability also can be addressed with cartilage procedures such as osteochondral allograft transplantation (OCA). Chahla et al.¹¹ performed a systematic review for OCA in the patellofemoral joint of 129 patients with at least 18 months of follow-up and found that mean survival rate was 87.9% and 77.2% at 5 and 10 years, respectively. When performing a meta-analysis to evaluate clinical outcomes for a variety of cartilage restoration procedures at >12 months' follow-up, Hinckel et al.¹² found that OCA had a greater failure rate (22.7%) compared with the overall failure rate. Here, we present a Technical Note for the treatment of chronic lateral patellar instability using a combined approach, including a shell OCA of the trochlea to address the trochlear dysplasia as well as the advanced arthritis, in addition to revision TTO, and revision MPFL reconstruction.

Surgical Technique (With Video Illustration)

Preoperative Evaluation and Surgical Decision-Making

Clinically, surgeons may suspect a diagnosis of patellar instability when patients present with complaints of anterior knee pain, recurrent subluxation episodes, or a noncontact twisting injury. A thorough physical examination to assess malalignment, joint laxity, and range of motion is assessed at the initial encounter. On examination, there may be evidence of tenderness on the medial aspect of the patella due to MPFL involvement, patellar apprehension with lateral translation of the patella, as well as a J sign during early flexion.

Four-view radiographs also should be obtained, including standing anteroposterior, flexion weight-bearing, lateral, and sunrise views. Trochlear dysplasia can be evaluated in lateral radiographic views with evidence of supratrochlear spur, crossing sign, and double contour sign. Patellar height and evidence of patella alta can be established in lateral view using the Caton–Deschamps Index method. Significant sulcus angle on sunrise radiographs greater than 140° further supports a diagnosis of trochlear dysplasia though is less reliable on radiographs. Computed tomography in the axial view can illicit TT-TG distance. In addition, magnetic resonance imaging is routinely used in this patient population due to its sensitivity for evaluating focal cartilage defects, tears to the MPFL, loose bodies,

patellofemoral arthritis, and other accompanying intra-articular pathology (Fig 1).

Patient Positioning and Anesthesia

The patient is placed in the supine position on a standard operating room table, and a regional adductor canal block is performed in addition to general anesthesia. A nonsterile tourniquet is applied proximally on the surgical extremity and placed in a leg holder (Mizuho OSI, Union City, CA) allowing 120° of knee flexion. The contralateral leg is then placed in an abduction stirrup with padding (Birkova Products, Gothenburg, NE). A pneumatic limb positioner (Spider2; Smith & Nephew, Andover, MA) is used for the operative leg to hold in the desired position during surgery. The site is then prepped and draped sterilely. During the final timeout, 2 g of cefazolin prophylaxis is administered. An examination under anesthesia demonstrates full range of motion and there is no evidence of anterior/posterior instability or varus/valgus deformity. A jumping J sign of 2 quadrants is seen when performing flexion and extension and there is difficulty centralizing the patella with tibial rotation alone. Mobility of the patella at 30° of flexion shows 2A lateralization (Video 1).

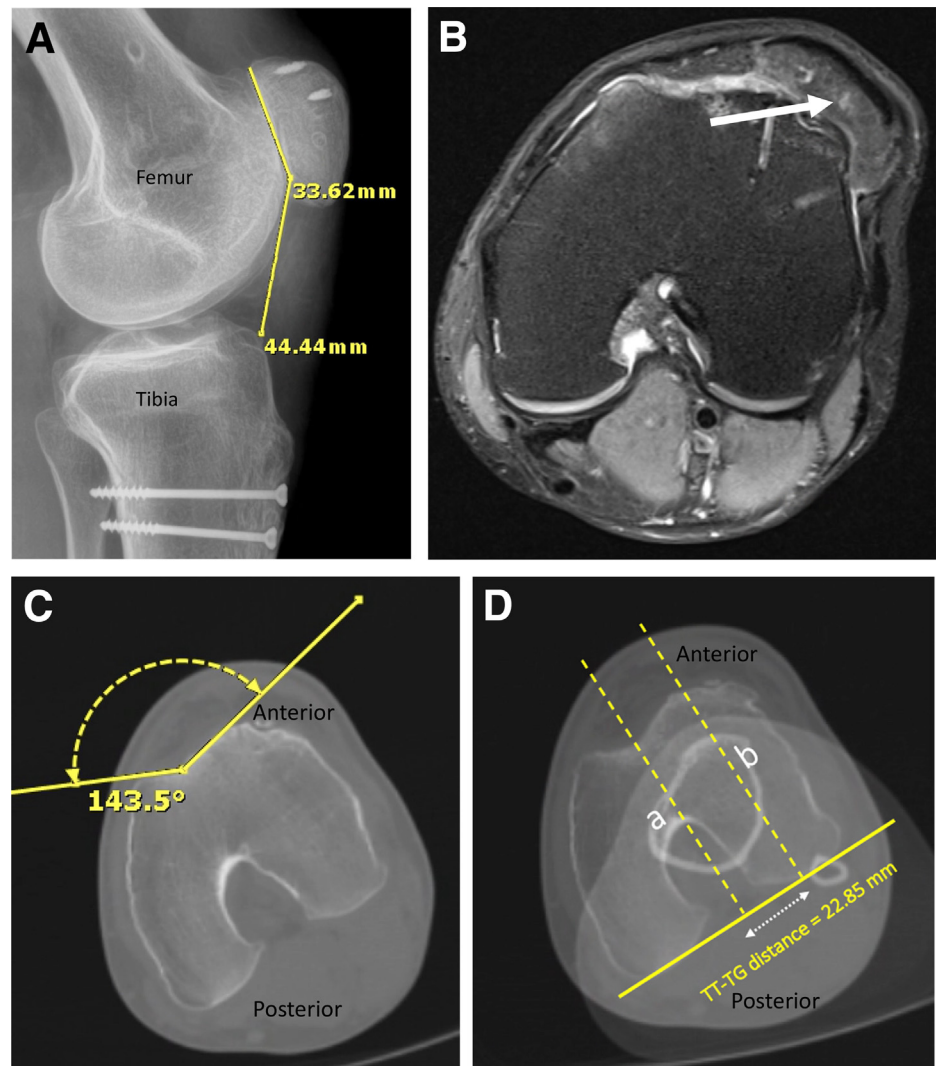
Diagnostic Arthroscopy

Two-portal diagnostic arthroscopy is performed through anterolateral and anteromedial portals to evaluate the trochlear dysplasia and determine whether any other accompanying intra-articular pathology is present in the joint. In addition to preoperative evaluation, diagnostic arthroscopy is critical to confirm and determine the needs for the procedures. Initial arthroscopic evaluation is then turned to the patellofemoral joint followed by evaluation of both the medial and lateral tibiofemoral compartments. Cartilage defects in the trochlea and patella as well as the shallow trochlear groove are confirmed during the patellofemoral compartment arthroscopy (Fig 2). After verifying that there are no accompanying meniscal and intra-articular ligament pathologies, arthroscopy is finalized and medial parapatellar arthrotomy is performed.

Surgical Approach

After sterile preparation of the left hip region, bone marrow aspirate concentrate is obtained at the iliac crest for application to the osteochondral allograft later in the case. Focus is then turned to the knee, where a medial parapatellar incision is performed following the same trajectory of the incision sites from the previous osteotomy and MPFL procedures (Fig 3). A blunt dissection is completed until the medial capsule of the knee is encountered. Electrocautery is used for a medial patellar arthrotomy while leaving approximately 2 mm of tissue attached to the patella to allow for later closure

Fig 1. Preoperative imaging of the left knee. Preoperatively obtained (A) lateral radiograph with left knee flexion at 30° indicating a Caton–Deschamps Index of 1.3 obtained from the patellar tendon length (44.44 mm) along the posterior surface divided by the length of the patella (33.62 mm). (B) Magnetic resonance imaging without contrast in axial view of the left knee revealing severe patellofemoral compartment chondromalacia with persistent lateral patellar tracking. (C) Axial view of the computed tomography (CT) scan without contrast of the left knee illustrates a sulcus angle of 143.5° consistent with trochlear dysplasia. (D) CT without contrast in axial view of the left knee with an increased tibial tubercle-trochlear groove (TT-TG) distance of 22.85 mm.



of the joint. Incision length should allow for complete visualization and access to expose the trochlea and the patellar surfaces as well as the tibial tubercle.

Osteochondral Allograft of the Trochlea and Patella

In the trochlea site, the knee is positioned at 60° of flexion. Guide pins are placed in the lateral gutter to enhance the visualization. Three 2.0-mm Kirschner wires are placed in parallel in a distal to proximal fashion to allow for exit on the proximal aspect of the trochlea and serve as a guide for the saw during removal of the existing native trochlea. Copious amounts of saline are applied during the removal process of the trochlea to avoid thermal necrosis of the bone with the oscillating bone saw. The patient's remaining bony surface is homogenized to ensure adequate fixation of the allograft in anatomic fashion.

Attention is shifted to preparation of the osteochondral allograft from the donor. Three guide pin Kirschner wires are placed bicortically through the fresh distal

femur allograft (JRF Ortho, Englewood, CO) with the first pin central and superior to the notch and the 2 other pins in parallel, just lateral and on either side to the first pin. The Kirschner wires assist in correct trajectory for creation of a desired graft when using the oscillating saw. Multiple trials of shaving the undersurface of the allograft are attempted to allow for the most anatomic reconstruction with the donor graft. Any remaining osteophytes on the outer edges of the graft or native knee are removed. Significant pulsatile irrigation (Pulsavac; Zimmer Biomet, Warsaw, IN) is then applied to the trochlear allograft. After the curvature match is confirmed, pressurized carbon dioxide is applied (CarboJet; Kinamed, Camarillo, CA) to the undersurface of the graft followed by application of the final product of 4 mL of bone marrow aspirate concentrate that was obtained at the beginning of the procedure from the patient's iliac crest and processed using a centrifuge (Arthrex Angel cPRP & Bone Marrow Processing System; Arthrex, Naples, FL). With the graft sitting

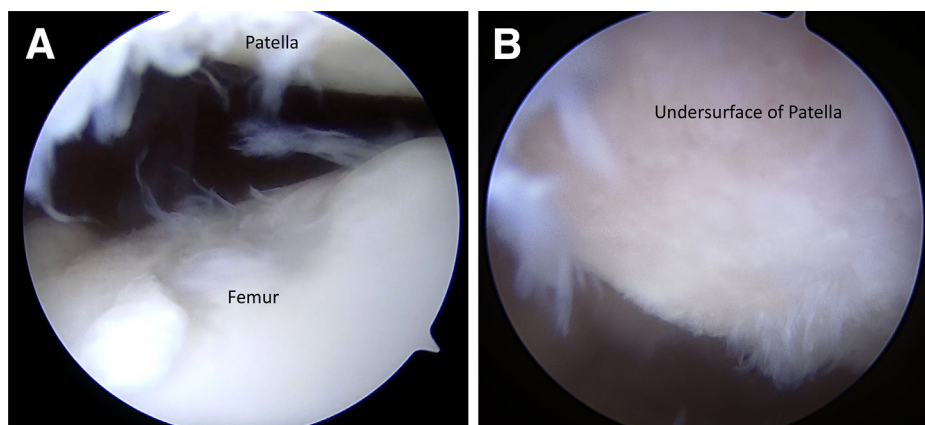


Fig 2. Diagnostic arthroscopy of the left knee. Two-portal diagnostic arthroscopy is performed through anterolateral and anteromedial portals with (A) evaluation of the articular surface of the trochlea and (B) undersurface of the patella before performing an open arthrotomy.

anatomically in position, 4 Kirschner wires are drilled on the distal medial and lateral as well as proximal medial and lateral allograft sides in the same transverse plane followed by placement of four headless screws (Acutrak Standard; Acumed, Hillsboro, OR) (Fig 4).

The defect to the patellar surface is identified and a guide pin is placed at the central aspect of the defect followed by application of an 18-mm scoring reamer to a depth of 8 mm until healthy bleeding bone is observed. Large amounts of saline are applied during the reaming process to minimize the risk of thermal necrosis to the bone and surrounding cartilage. A ruler measures the depth of the needed graft using a coordinate system approach (3/6/9/12-o'clock positions), which ensures an accurate fit of the donor allograft. The patellar allograft (JRF Ortho) is outlined with a marking pen and the depths corresponding to the dimensions of the coordinate system of the patient's defect site. A saw helps to form the correct dimensions of the osteochondral plug under continuous application of saline. Significant irrigation (Pulsavac; Zimmer Biomet)

followed by pressurized carbon dioxide (CarboJet; Kinamed) is applied to the undersurface of the patellar graft. The graft is then secured in a press-fit fashion without the need for any screw fixation (Fig 5).

Revision TTO

After addressing the chondral surface of the trochlea and before addressing the patella with the osteochondral allograft, the knee is taken through a series of different degrees of flexion. In the presence of a continued lateral J sign, a revision TTO is indicated based on the intraoperative examination and preoperative radiological TT-TG measurement. In this case, the patella was now entering into a normal groove but its starting point was still lateral. Screws from the previous osteotomy are identified and attempted to be removed, if possible, before performing a revision TTO. The cut is accomplished from the medial aspect of the tibial tubercle at 30° of inclination. Following the osteotomy, three 4-mm, evenly spaced cannulated screws (Arthrex) are placed to fix the tibial tubercle segment after appropriate

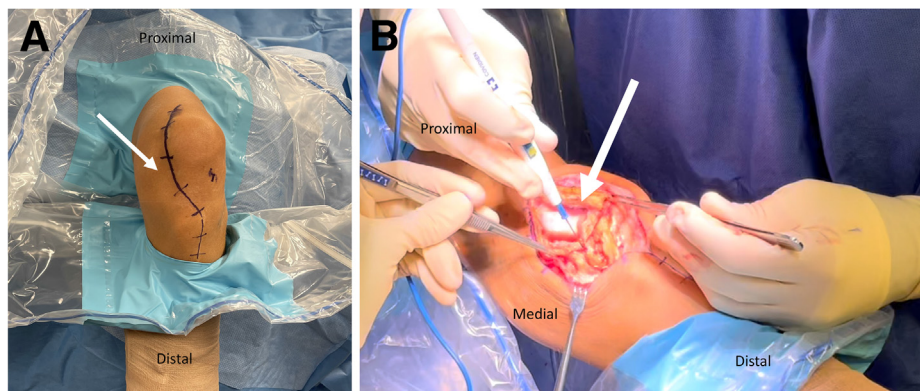


Fig 3. Preparation of surgical incision of the left knee. (A) A line is drawn for the medial parapatellar incision following the same trajectory of the incision sites from the previous osteotomy and medial patellofemoral ligament procedures starting at the superior pull of the patella and extending inferiorly to about 5 cm below the tibial tubercle. (B) Medial parapatellar arthrotomy is performed with the left knee in full extension using radiofrequency ablation for exposure.

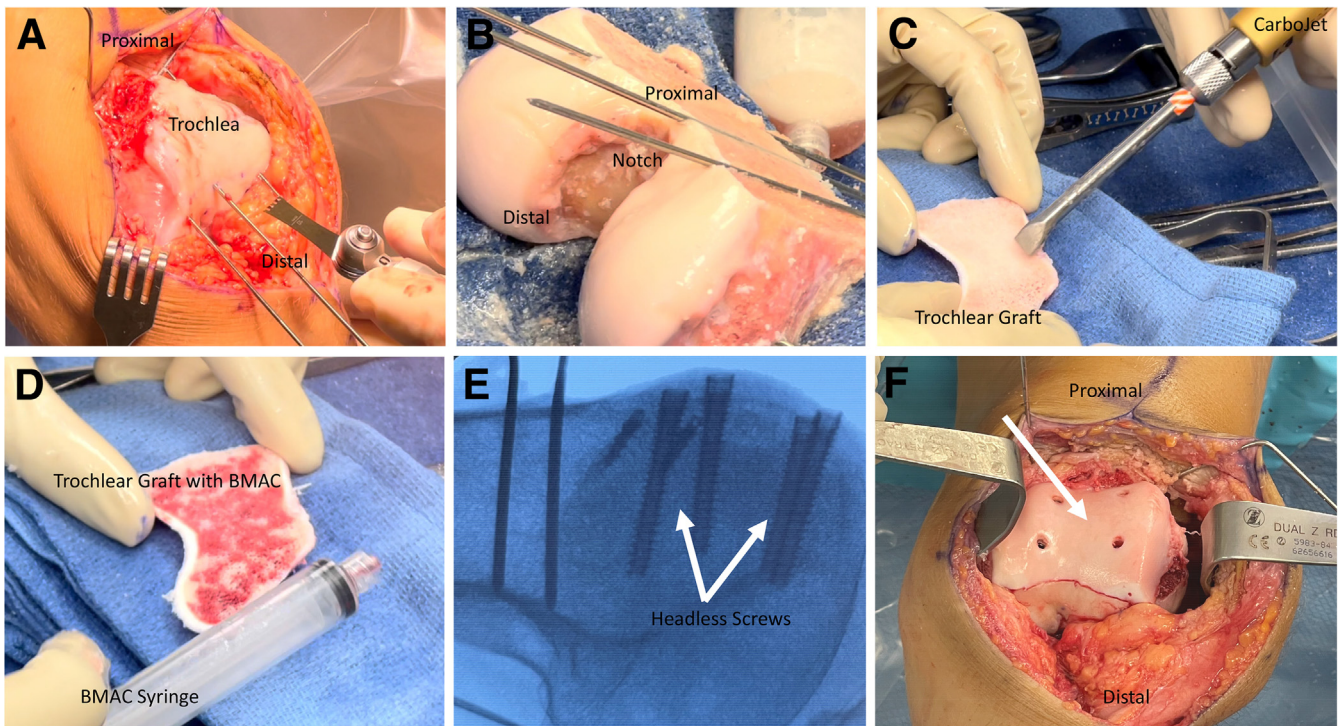


Fig 4. Intraoperative left knee trochlear shell osteochondral transplantation preparation. (A) Three 2.0-mm Kirschner wires are placed in parallel in a distal to proximal fashion to allow for exit on the proximal aspect of the trochlea and serve as a guide for the saw during removal of the existing native trochlea. (B) Three guide pin Kirschner wires are placed bicortically through the fresh allograft (JRF Ortho) with the first pin central and superior to the notch and the 2 other pins on either side to the first pin followed by removal of the graft with an oscillating bone saw. (C) Pressurized carbon dioxide is applied (CarboJet; Kinamed) to the undersurface of the trochlear graft. (D) Application of 4 mL of bone marrow aspirate concentrate is applied to the undersurface of the trochlear graft after application of the pressurized carbon dioxide. (E) Confirmation of placement of the 4 headless screws (Acutrak Standard; Acumed) in the trochlear osteochondral allograft on fluoroscopy intraoperatively. (F) Finalized trochlear osteochondral allograft sitting anatomically in position.

medialization. The knee is then taken through a range of motion and the patella is checked for any signs of patellar maltracking. The screw positioning and fixation

is confirmed with intraoperative fluoroscopy. The preparation of the patellar osteochondral allograft is now addressed as described previously.

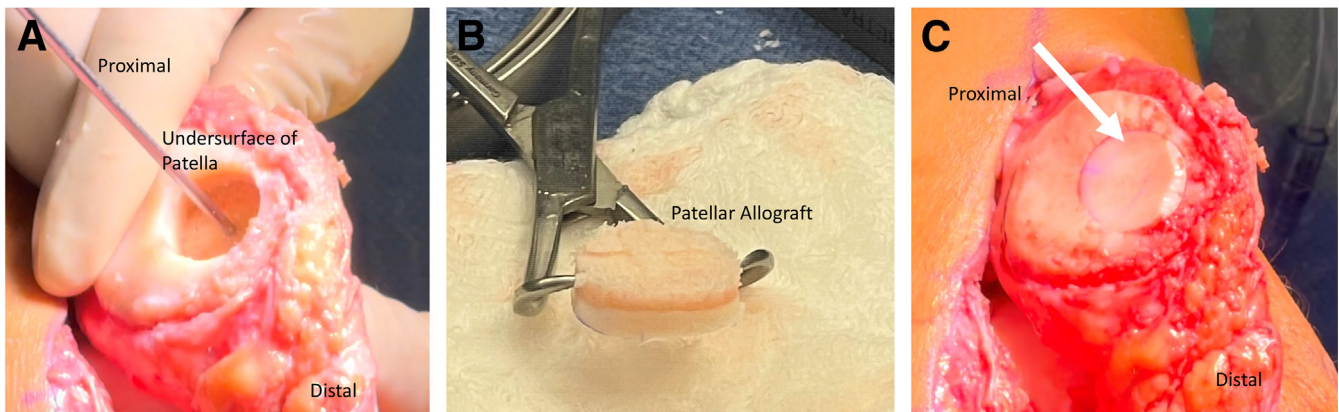


Fig 5. Intraoperative left knee patellar osteochondral transplantation preparation. (A) A guide pin is placed at the central aspect of the defect followed by application of an 18-mm scoring reamer to a depth of 8 mm until healthy bleeding bone is observed. (B) Final preparation of the donor patellar osteochondral allograft before insertion into the patient's patellar defect site. (C) Undersurface of the patella after the patellar osteochondral graft is press-fit into place.

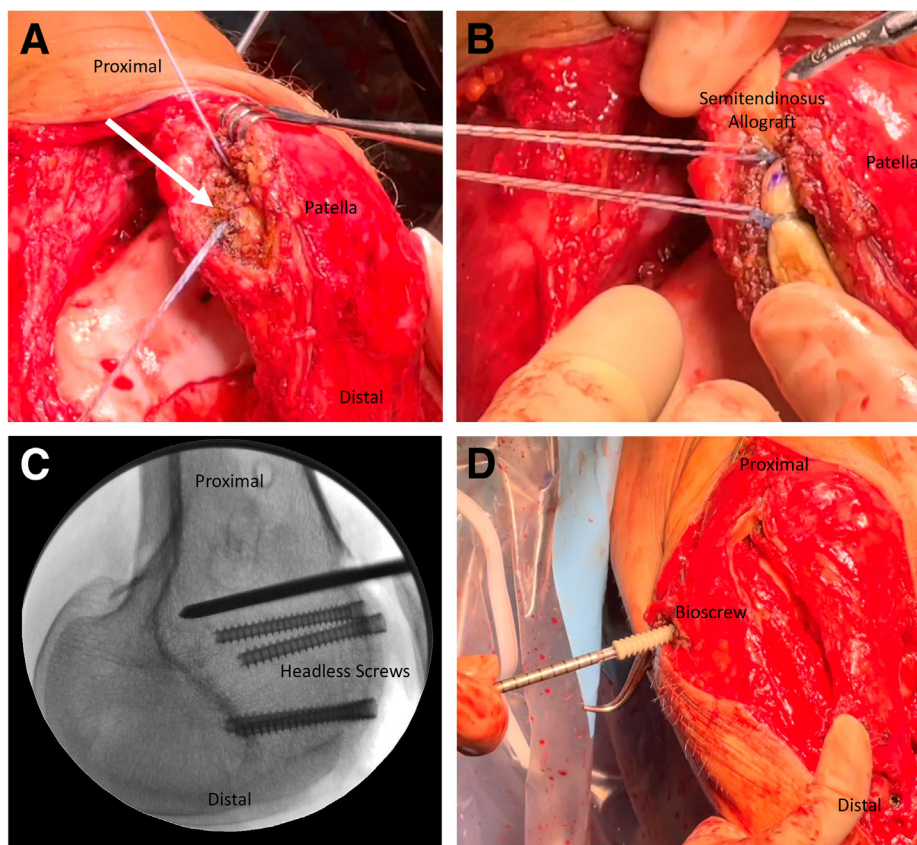


Fig 6. Preparation of the left knee revision medial patellofemoral ligament (MPFL) graft. (A) A 15-mm long osteal trough on the medial and proximal third of the patellar edge is created followed by application of a 1.8-mm all-suture anchor (Q-Fix; Smith & Nephew) to drill a tunnel to a depth of 18 mm at a 45° angle parallel to the frontal patellar plane followed by deployment of the implant suture device through the predrilled hole. Both suture anchors should be secured in the proximal half of the medial patellar surface with the second anchor 15 mm proximal from the first anchor. (B) The semitendinosus allograft (AlloSource) is placed between the 2 anchors from its midpoint on the medial patellar bone surface and secured in place. (C) Intraoperative fluoroscopy with lateral view of the distal femur. A Kirschner wire followed by a 7-mm reamer is inserted in the distal medial femur at the femoral footprint of the MPFL 2.5 mm distal to posterior aspect of the medial femoral condyle and 1 mm anterior to the extension of the posterior cortex and just proximal to the Blumensaat line. (D) The semitendinosus allograft is shuttled beneath the fascia between the second (MPFL and medial collateral ligament) and third (medial patellomeniscal and patellofemoral ligament/joint capsule) layers and exits the medial skin incision, followed by insertion of both tendon ends through the femoral tunnel. The MPFL allograft is secured with a 7-mm × 30-mm bioscrew (Smith & Nephew) on the distal medial femur.

Revision MPFL Reconstruction

Attention is then turned to the distal medial femur to locate the femoral footprint of the MPFL: 2.5 mm distal to the posterior aspect of the medial femoral condyle, 1 mm anterior to the extension of the posterior cortex of the femur, and just proximal to the Blumensaat line.¹³⁻¹⁵ The placement of the guide pin is checked under fluoroscopy to accurately determine these measurements. A Kirschner wire is then drilled from the medial side of the femur at a 45° proximal angle through the lateral cortex, followed by application of a 7-mm reamer over the kirschner wire. The length of the 7-mm tunnel is determined based on the graft length and is usually 30 mm in length. The Kirschner wire is left in place after creating the tunnel (Fig 6). The Kirschner wire then helps to facilitate movement of the

double-loaded passing suture through the femoral tunnel.

After identifying the medial bone surface of the patella and removing all soft tissue, a rongeur is used to create a 15-mm long osteal trough on the medial and proximal third of the patellar edge. A 1.8-mm all-suture anchor (Q-Fix; Smith & Nephew) is used to drill a tunnel to a depth of 18 mm at a 45° angle parallel to the frontal patellar plane followed by deployment of the implant suture device through the predrilled hole. This process is then repeated approximately 15 mm more proximal from the initial drill site (Fig 6). Both suture anchors should be secured in the proximal half of the medial patellar surface. The semitendinosus allograft (AlloSource, Centennial, CO) is placed between the 2 anchors from its midpoint on the medial patellar bone

Table 1. Pearls and Pitfalls

Pearls

- Multiple trials of shaving the undersurface of the trochlear allograft are attempted to allow for the most anatomic reconstruction with the donor graft. This is done before securing the graft on the distal femur.
- Pressurized carbon dioxide is applied to the undersurface of the trochlear graft after finalizing the graft preparation to remove bone remnant particles and clean the bone microarchitecture just before the BMAC application.
- BMAC application to the undersurface of the trochlear graft may enhance biologic graft incorporation.
- Performing a patellar osteochondral allograft procedure after osteotomy of the tibial tubercle segment allows for a better view of the patella and avoids iatrogenic extensor mechanism injuries.
- A ruler measures the depth of the needed patellar graft using a coordinate system approach (3/6/9/12-o'clock positions), which ensures an accurate donor–host curvature match.

Pitfalls

- Due to the extensive amount of bone cutting of the osteochondral allografts, there is a greater risk of thermal necrosis to the bone and potential for poor healing after surgery in cases in which saline is not used.
- Inaccurate curvature match between the donor and host may result in inferior outcomes following an osteochondral allograft.
- Improper identification of the MPFL attachment sites on the femur and patella can affect the biomechanical stability of the patellofemoral joint during flexion and extension and thus results in worsening patellar instability.

BMAC, bone marrow aspirate concentrate; MPFL, medial patellofemoral ligament.

surface and secured in place. This allows the graft to be of equal terminal lengths when it is fixated on the patella. A high-strength suture (ULTRABRAID; Smith & Nephew) is used to suture each tendon end, which helps to make pass of the graft through the femoral tunnel. The soft tissue is medially dissected between the second (MPFL and medial collateral ligament) and third (medial patellomeniscal and patellotibial ligament/joint capsule) layers with careful attention of not damaging the knee capsule. The graft is brought between the second and third layers and exits at the femoral insertion site, followed by insertion of both tendon ends through the femoral tunnel using the passing suture previously placed into the femoral tunnel (Fig 6). The graft is secured in place with a 7-mm × 30-mm bio-screw (Smith & Nephew) on the distal medial femur with the knee in 20° of flexion. Once secured, the knee is taken through range of motion from 0 to 120° to ensure adequate reconstruction. A similar layered closure of the incision is performed and a sterile dressing is applied to the surgical site followed by a locked knee brace.

Rehabilitation

In the initial postoperative period from 0 to 6 weeks, there is strict non–weight-bearing status with crutches and use of a knee immobilizer until quadricep control is

adequate. During this time, focus is directed to quadricep strengthening, patellar mobilization, and straight leg raises. From 6 to 8 weeks postoperatively, patients are progressed to full weight-bearing and can discontinue the knee immobilizer. Active range of motion exercises are begun during this time with the goal of advancing to full range of motion. Therapy now adds a focus on core hip strengthening. Introduction of a stationary bike to facilitate improvement of range of motion is also started. At 8 to 12 weeks postoperative, closed-chain activities are initiated, including wall sits, mini-squats, and shuttle movements. Around 12 weeks postoperative, there is a shift to progressive active strengthening. Patients should expect to have normal pain-free gait around 12 weeks but may be delayed due to the complexity of the aforementioned surgical procedure.

Discussion

The MPFL is the major restraint to lateral patellar translation from full extension through the first 20° to 70° of knee flexion.¹⁰ In cases in which normal patellar tracking is compromised, reconstruction of the MPFL has been reported as an effective intervention to stabilize the patella and improve a patient's function and quality of life. Biomechanically, MPFL reconstruction, using either a single-bundle or double-bundle technique, has been shown to adequately restore patellar stability and resistance to lateral flexion.¹⁶ Allen et al.⁷ performed a retrospective review of 30 knees in 28 patients with recurrent lateral patellar instability who underwent a combined MPFL reconstruction with TTO at their institution and had at least 2-year follow up. They found that the Caton–Deschamps Index decreased by a mean of 0.2 and although 30% of patients still had patella alta postoperatively and 83% of all those participating in organized sports were able to return to play. The authors also found that female gender and medialization greater than 10 mm were associated with statistically significant worse functional outcomes, lower Kujala, and lower International Knee Documentation Committee scores. A major advantage of MPFL reconstruction for patellar instability is that the

Table 2. Advantages and Limitations

Advantages

- Trochlear osteochondral allograft is a potential option in patients with existing advanced osteoarthritis, as it can re-establish the appropriate articular surface and trochlear groove at the same time.
- Shell osteochondral allograft can better address significant trochlear dysplasia compared with cylindrical allografts.

Limitations

- Given that osteochondral allograft in this patient presentation requires a large graft size and is inherently foreign to a patient's body, there is potential for difficulty with complete integration in the recipient.

technique outlined in this study allows for an anatomic reconstruction using a semitendinosus tendon allograft, which is stronger than the original MPFL and stronger than other graft options like the gracilis tendon.^{17,18}

In addition to the MPFL, anatomical consideration of the size and shape of the trochlea is crucial in restoring patellar stability. While the MPFL is the major restraint to lateral patellar tracking until 70° of flexion, the trochlea serves as the major restraint to patellar instability for the remainder of knee flexion.¹⁰ A dysplastic shallow trochlear groove can decrease the knee's intrinsic anatomical resistance to patellar maltracking, making its overall stability comparable to a knee with an incompetent MPFL.¹⁰ While trochleoplasty is an effective treatment modality for addressing trochlear dysplasia in the context of patellar instability, it is not a viable therapeutic intervention for patients with advanced degenerative patellofemoral changes.¹

To sufficiently treat a dysplastic trochlea with concomitant patellofemoral arthritis and high-grade chondromalacia, a bipolar osteochondral allograft transplantation can be performed as a salvage procedure. Osteochondral allograft transplantation can adequately address cartilage lesions, and long-term efficacy has been reported for osteochondral allograft transplantation to treat chondral defects of the knee.¹⁹ Unlike the use of osteochondral allografts in the management of isolated chondral defects, there is limited literature discussing its use with associated patellar instability. Several case reports have outlined the successful short-term outcomes of managing trochlear dysplasia and patellofemoral chondromalacia with a unipolar osteochondral allograft transplant and TTO.^{1,20} DePhillipo et al.¹ reported on a 21-year-old female patient with recurrent lateral patellar instability and noted that the patient was not a candidate for a trochleoplasty procedure, given the degree and diffuse nature of the grade IV-trochlear chondromalacia, and instead underwent an osteochondral allograft procedure. Surgeons considering trochleoplasty must be careful when contemplating this surgical option, as inability to correct an existing deformity can lead to or rapidly progress underlying chondral damage. While both authors reported positive initial results, only Vansadia et al.²⁰ performed a concomitant MPFL reconstruction. To date, only one study by Mirzayan et al.²¹ has reported on the clinical outcomes after a bipolar osteochondral allograft technique was used to address trochlear dysplasia. The authors reported good graft integration, significant functional improvement, pain relief, improvement in activity level, and prevention of recurrent instability.

In this study, a bipolar osteochondral allograft transplantation technique is used to treat both the patellar and trochlear pathology, combined with an MPFL reconstruction and TTO. The advantage of the technique presented here is that a shell osteochondral

allograft approach can better address significant trochlear dysplasia compared with cylindrical allografts and can reestablish the appropriate articular surface and trochlear groove at the same time in those with advanced osteoarthritis. Comparatively, the main limitation with the current technique is that it requires a large graft size and the inherently foreign nature of an allograft can lead to incomplete integration in the recipient (Tables 1 and 2). Surgeons dealing with young patients who have extensive patellofemoral arthritis and chronic patellar instability may find this surgical approach beneficial to re-establish the appropriate articular surface and minimize the need for a total knee arthroplasty procedure at such an early age.

References

1. DePhillipo NN, Kennedy MI, Aman ZS, Moatshe G, LaPrade RF. Osteoarticular allograft transplantation of the trochlear groove for trochlear dysplasia: A case report. *JBJS Case Connect* 2018;8:e29.
2. LaPrade RF, Cram TR, James EW, Rasmussen MT. Trochlear dysplasia and the role of trochleoplasty. *Clin Sports Med* 2014;33:531-545.
3. Carstensen SE, Menzer HM, Diduch DR. Patellar instability: When is trochleoplasty necessary? *Sports Med Arthrosc Rev* 2017;25:92-99.
4. Erickson BJ, Nguyen J, Gasik K, Gruber S, Brady J, Shubin Stein BE. Isolated medial patellofemoral ligament reconstruction for patellar instability regardless of tibial tubercle-trochlear groove distance and patellar height: Outcomes at 1 and 2 years. *Am J Sports Med* 2019;47:1331-1337.
5. Cregar WM, Huddleston HP, Wong SE, Farr J, Yanke AB. Inconsistencies in reporting risk factors for medial patellofemoral ligament reconstruction failure: A systematic review [published online April 29, 2021]. *Am J Sports Med*. <https://doi.org/10.1177/03635465211003342>.
6. Brady JM, Sullivan JP, Nguyen J, et al. The tibial tubercle-to-trochlear groove distance is reliable in the setting of trochlear dysplasia, and superior to the tibial tubercle-to-posterior cruciate ligament distance when evaluating coronal malalignment in patellofemoral instability. *Arthroscopy* 2017;33:2026-2034.
7. Allen MM, Krych AJ, Johnson NR, Mohan R, Stuart MJ, Dahm DL. Combined tibial tubercle osteotomy and medial patellofemoral ligament reconstruction for recurrent lateral patellar instability in patients with multiple anatomic risk factors. *Arthroscopy* 2018;34:2420-2426.e3.
8. Ren B, Zhang X, Zhang L, et al. Isolated trochleoplasty for recurrent patellar dislocation has lower outcome and higher residual instability compared with combined MPFL and trochleoplasty: A systematic review. *Arch Orthop Trauma Surg* 2019;139:1617-1624.
9. Davies MR, Allahabadi S, Diab TE, et al. Sulcus-deepening trochleoplasty as an isolated or combined treatment strategy for patellar instability and trochlear dysplasia: A systematic review. *Arthrosc Sports Med Rehabil* 2020;2:e661-e669.
10. Nolan JE 3rd, Schottel PC, Endres NK. Trochleoplasty: Indications and technique. *Curr Rev Musculoskelet Med* 2018;11:231-240.

11. Chahla J, Sweet MC, Okoroa KR, et al. Osteochondral allograft transplantation in the patellofemoral joint: A systematic review. *Am J Sports Med* 2019;47:3009-3018.
12. Hinckel BB, Pratte EL, Baumann CA, et al. Patellofemoral cartilage restoration: A systematic review and meta-analysis of clinical outcomes. *Am J Sports Med* 2020;48:1756-1772.
13. Smith and Nephew. Q-Fix All-Suture Implants Technique Guide. Online, <https://www.smithnephew.com/documents/education%20and%20evidence/literature/2016/mpfl-technique-guide-scheffler.pdf>. Accessed September 1, 2021.
14. Baldwin JL. The anatomy of the medial patellofemoral ligament. *Am J Sports Med* 2009;37:2355-2361.
15. Schöttle PB, Schmeling A, Rosenstiel N, Weiler A. Radiographic landmarks for femoral tunnel placement in medial patellofemoral ligament reconstruction. *Am J Sports Med* 2007;35:801-804.
16. Wang Q, Huang W, Cai D, Huang H. Biomechanical comparison of single- and double-bundle medial patellofemoral ligament reconstruction. *J Orthop Surg Res* 2017;12:29.
17. Ladenhauf HN, Berkes MB, Green DW. Medial patellofemoral ligament reconstruction using hamstring autograft in children and adolescents. *Arthrosc Tech* 2013;2:e151-e154.
18. Migliorini F, Trivellas A, Driessen A, Quack V, Tingart M, Eschweiler J. Graft choice for isolated MPFL reconstruction: Gracilis versus semitendinosus [published correction appears in *Eur J Orthop Surg Traumatol* 2021;31:1255]. *Eur J Orthop Surg Traumatol* 2020;30:763-770.
19. Familiari F, Cinque ME, Chahla J, et al. Clinical outcomes and failure rates of osteochondral allograft transplantation in the knee: A systematic review. *Am J Sports Med* 2018;46:3541-3549.
20. Vansadia DV, Heltsley JR, Montgomery S, Suri M, Jones DG. Osteochondral allograft transplantation for femoral trochlear dysplasia. *Ochsner J* 2016;16:475-480.
21. Mirzayan R, Charles MD, Batech M, Suh BD, DeWitt D. Bipolar osteochondral allograft transplantation of the patella and trochlea. *Cartilage* 2020;11:431-440.