

Quantitative and Qualitative Analysis of the Medial Patellar Ligaments

An Anatomic and Radiographic Study

Bradley M. Kruckeberg,* BA, Jorge Chahla,* MD, PhD, Gilbert Moatshe,^{†‡§} MD, Mark E. Cinque,* BS, Kyle J. Muckenhirn,* BS, Jonathan A. Godin,[†] MD, MBA, Taylor J. Ridley,^{||} MD, Alex W. Brady,* MSc, Elizabeth A. Arendt,^{||} MD, and Robert F. LaPrade,*^{†¶} MD, PhD
Investigation performed at Steadman Philippon Research Institute, Vail, Colorado, USA

Background: The qualitative and quantitative anatomy of the medial patellar stabilizers has been reported; however, a quantitative analysis of the anatomic and radiographic attachments of all 4 ligaments relative to anatomic and osseous landmarks, as well as to one another, has yet to be performed.

Purpose: To perform a qualitative and quantitative anatomic and radiographic evaluation of the medial patellofemoral ligament (MPFL), medial patellotibial ligament (MPTL), medial patellomeniscal ligament (MPML), and medial quadriceps tendon femoral ligament (MQTFL) attachment sites, with attention to their relationship to pertinent osseous and soft tissue landmarks.

Study Design: Descriptive laboratory study.

Methods: Ten nonpaired fresh-frozen human cadaveric knees were dissected, and the MPFL, MPTL, MPML, and MQTFL were identified. A coordinate measuring device quantified the attachment areas of each structure and its relationship to pertinent bony landmarks. Radiographic analysis was performed through ligament attachment sites and relevant anatomic structures to assess their locations relative to pertinent bony landmarks.

Results: Four separate medial patellar ligaments were identified in all specimens. The center of the MPFL attachments was 14.3 mm proximal and 2.1 mm posterior to the medial epicondyle and 8.3 mm distal and 2.7 mm anterior to the adductor tubercle on the femur and 8.9 mm distal and 19.9 mm medial to the superior pole on the patella. The MQTFL had a mean insertion length of 29.3 mm on the medial aspect of the distal quadriceps tendon. The MPTL and MPML shared a common patellar insertion and were 9.1 mm proximal and 15.4 mm medial to the inferior pole. The MPTL attachment inserted on a newly identified bony ridge, which was located 5.0 mm distal to the joint line. The orientation angles of the MPTL and MPML with respect to the patellar tendon were 8.3° and 22.7°, respectively.

Conclusion: The most important findings of this study were the correlative anatomy of 4 distinct medial patellar ligaments (MPFL, MPTL, MPML, MQTFL), as well as the identification of a bony ridge on the medial proximal tibia that consistently served as the attachment site for the MPTL. The quantitative and radiographic measurements, while comparable with current literature, detailed the meniscal insertion of the MPML and defined a patellar insertion of the MPTL and the MPML as a single attachment. The data allow for reproducible landmarks to be established from previously known bony and soft tissue structures.

Clinical Relevance: The findings of this study provide the anatomic foundation needed for an improved understanding of the role of medial-sided patellar restraints. This will help to further refine injury patterns and/or soft tissue deficiencies that result in lateral patellar instability, which can then be addressed with an anatomic-based reconstruction or repair technique and potentially lead to improved outcomes.

Keywords: knee; patellofemoral joint; medial patellotibial ligament; medial patellofemoral ligament; medial patellomeniscal ligament; lateral patellar instability; medial quadriceps tendon femoral ligament; quantitative anatomy

Lateral patellar dislocations account for 2% to 3% of all knee injuries and are the second-leading cause of traumatic knee hemarthroses.^{1,23} The main medial knee structures

responsible for stabilization of the patellofemoral joint are the medial patellofemoral ligament (MPFL), the medial patellotibial ligament (MPTL), and the medial patellomeniscal ligament (MPML).²³ The MPFL is the most commonly injured ligament with a lateral patellar dislocation,^{2,26,30,41} but less is known about the MPTL and MPML in acute lateral patellar dislocations. However, magnetic resonance imaging evidence suggests that the MPTL is also torn in

primary lateral patellar dislocations.³⁸ Injury to these 3 ligaments and subsequent patellofemoral joint lateral dislocation can lead to altered contact forces and joint degeneration.^{17,19}

Several studies have reported on the anatomy and biomechanics of the MPFL,^{7,8,21-23} but few have investigated the MPTL and MPML. Philippot et al²³ recently evaluated the medial ligamentous patella stabilizers from 0° to 90° of flexion, reporting that the MPFL was the primary medial stabilizer of the patella in the first 30° of flexion, while the MPTL and MPML have an increased role in restriction of lateral translation, patellar tilt, and patellar rotation at 90° of flexion when compared with full extension. Although this was a combined assessment of the MPTL and MPML, these 2 ligaments appear to have an important role in maintaining normal kinematics of the patellofemoral joint, particularly at higher flexion angles. Additionally, anatomic evaluation of the MPFL has shown an attachment to the quadriceps tendon via the proximal fibers of the MPFL, known as the medial quadriceps tendon femoral ligament (MQTFL).²⁰ This has biomechanical implications, as this would indicate that the MPFL pulls the quadriceps tendon and patella directly, controlling them as a single unit.

Nonoperative management of lateral patellar dislocations is associated with recurrent dislocations in 35% to 50% of patients, including those patients with uncorrected dysplastic factors.⁴⁻⁶ In the setting of recurrent lateral patellar instability, surgical reconstruction is typically recommended, including MPFL reconstruction with adjuvant bony and soft tissue procedures, depending on associated anatomic instability factors.^{10,24,40} Although the incidence of redislocation after MPFL reconstruction is low in the current literature,³⁷ there is a relatively high incidence of complications,²⁹ particularly continued apprehension and/or subluxation without frank dislocation. This, with the clinical failure rate, necessitates further investigation into the limitations of our current surgical algorithm. A better anatomic and biomechanical understanding of these structures will provide the foundation for improved reconstruction techniques and their respective indications.

The purpose of this study was to perform a quantitative and qualitative anatomic and radiographic evaluation of the MPFL, MPTL, MPML, and MQTFL attachment sites, with attention to their relationship to pertinent osseous and soft tissue landmarks. It was hypothesized that the MPFL, MPTL, MPML, and MQTFL will have definable parameters concerning their anatomic attachments and consistent relationships to one another, as well as pertinent, surgically relevant landmarks with correlative radiographic findings.

METHODS

Specimen Preparation

Ten nonpaired fresh-frozen human cadaveric knees (mean age, 56.2 years; range, 35-63 years; 5 right, 5 left; 6 males, 4 females) without previous injury, surgery, or a history of knee arthritis were utilized for this study. After dissection of subcutaneous tissue, the MPFL, MPTL, MPML, and MQTFL were identified by a combined outside-in and inside-out anatomic dissection. The MPFL was identified deep to the vastus medialis oblique (VMO) and subsequently dissected. The MPFL fibers were then followed to the femoral, patellar, and quadriceps tendon (MQTFL) attachments. For the inside-out dissection of the MPTL and MPML, a lateral arthrotomy was performed, the Hoffa fat pad was removed, and the patella was reflected medially. The synovium and the capsule on the anteromedial aspect of the knee were carefully dissected, and the MPTL and MPML were both identified by first exposing their attachments to the patella and then following their fibers distally to their tibial and meniscal attachments, respectively. The soft tissues surrounding the MPTL and MPML were resected, leaving their attachments intact. The femur was then clamped, and 2 Steinmann pins rigidly fixed the femur to the tibia at 90° of knee flexion and neutral knee rotation for measurement consistency. With the knee fixed at 90° of knee flexion, the quadriceps tendon was tensioned by hand in a vector aligned with the femur to engage the patella in the trochlear groove. The patella was then fixed to the femur with 2 Steinmann pins to allow consistent pull on the medial soft tissue structures and to prevent patellar translation, tilt, and rotation.

Qualitative and Quantitative Anatomy

Coordinates of anatomic landmarks were measured with a portable coordinate measuring device (7315 Romer Absolute Arm; Hexagon Metrology) to establish the femoral, patellar, and tibial anatomic axes.^{13,43} Pertinent bony and soft tissue landmarks (Table 1) for the MPFL, MPTL, and MPML were identified and recorded with the coordinate measuring device. Patellar tendon orientation was determined through the inferior pole of the patella and the tibial tubercle in the coronal plane. Furthermore, approximate ligament lengths were calculated via the distance between the 2 attachment centers for each ligament. The soft tissue attachment of the MQTFL on the quadriceps tendon was measured

*Address correspondence to Robert F. LaPrade, MD, PhD, Steadman Philippon Research Institute, The Steadman Clinic, 181 West Meadow Drive, Suite 400, Vail, CO 81657, USA (email: rlaprade@thesteadmanclinic.com).

*Steadman Philippon Research Institute, Vail, Colorado, USA.

†The Steadman Clinic, Vail, Colorado, USA.

‡Oslo University Hospital and University of Oslo, Oslo, Norway.

§Norwegian School of Sports Sciences, Oslo Sports Trauma Research Center, Oslo, Norway.

||Department of Orthopedic Surgery, University of Minnesota, Minneapolis, Minnesota, USA.

One or more of the authors has declared the following potential conflict of interest or source of funding: R.F.L. receives royalties from Arthrex Inc and Smith & Nephew; is a paid consultant for Arthrex Inc, Ossur, and Smith & Nephew; and receives research support from Arthrex Inc, Smith & Nephew, Ossur, and Linvatec. E.A.A. is a paid consultant for Smith & Nephew.

TABLE 1
Anatomic Points Measured in Quantitative Analysis^a

Bony Landmark	Soft Tissue
Adductor tubercle	MPFL femoral/patellar attachment
Gastrocnemius tubercle	MPTL tibial/patellar attachment
Medial epicondyle	MPML patellar/meniscal attachment
Superior pole of patella	sMCL anterior border
Inferior pole of patella	MQTFL quadriceps tendon attachment
Patella articular cartilage line	
Tibial tubercle	
Gerdy tubercle	
Medial tibial tubercle	

^aMPFL, medial patellofemoral ligament; MPML, medial patello-meniscal ligament; MPTL, medial patellotibial ligament; MQTFL, medial quadriceps tendon femoral ligament; sMCL, superficial medial collateral ligament.

with a digital caliper (Swiss Precision Instruments Inc) with a manufacturer-reported accuracy of 0.03 mm.

Radiographic Analysis

After structure identification, 4.5-mm radio-opaque spheres (Crosman Corporation) were inserted flush with the cortical bone into the center of the attachment sites. True anteroposterior (AP)¹⁸ and lateral^{25,42} (with the knee in 90° of flexion) radiographs were obtained with a fluoroscopic miniature C-arm (Hologic Inc). On the AP views, distances between attachments and pertinent bony landmarks and from the femoral condylar line and tibial plateau line were taken as previously described.¹⁶ Additionally, reference lines were drawn on the AP and lateral views, as previously described,^{25,28,42} to calculate the distances from the Blumensaat line, the posterior femoral cortex, the diaphyseal axis of the tibia, and the femoral condylar line. Lateral radiographs were obtained at 90° of flexion with the Steinmann pins remaining in the patella to better replicate the correct anatomic position before dissection. AP views were then obtained with the Steinmann pins removed.

Two authors, a board-certified orthopaedic surgeon and a fourth-year medical student, performed the measurements (J.A.G. and M.E.C.). Each observer was blinded to the other's readings. All measurements were made in reference to the centers of structures' attachment sites and are reported as mean and 95% CI. Interrater reliability of individual radiograph examiners was assessed with the 2-way random-effects, single-measures interrater correlation coefficient.⁹ Once acceptable agreement between readers was confirmed, all mean distance measurements were based on the primary radiograph examiner.

Statistical Analysis

Data were analyzed with custom software (MATLAB 2016b; The MathWorks Inc). Distance measurements were calculated as the 3-dimensional (3D) linear distance between structures and are referred to as *direct distances*. Unless otherwise noted,

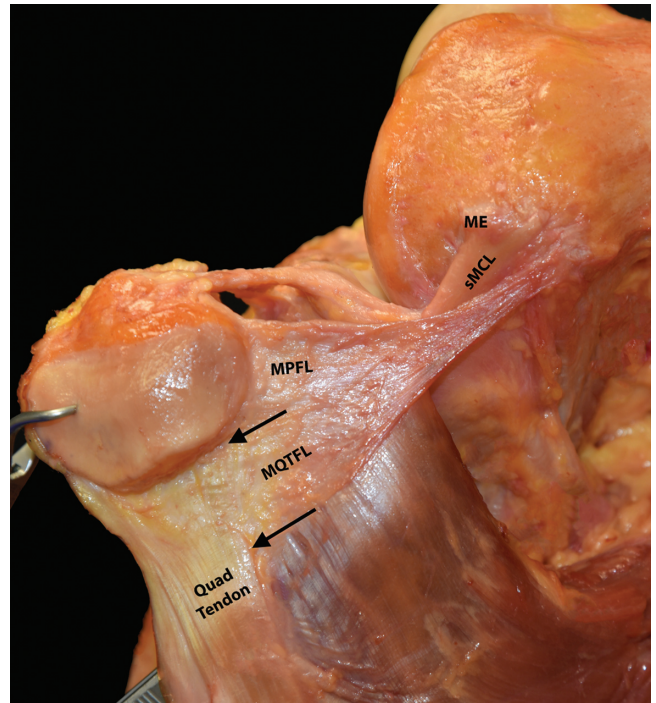


Figure 1. Medial view of a right knee demonstrating the MPFL femoral and patellar attachments and the attachment of the MPQTFL to the quadriceps tendon (arrows). ME, medial epicondyle; MPFL, medial patellofemoral ligament; MQTFL, medial quadriceps tendon femoral ligament; sMCL, superficial medial collateral ligament.

all anatomic distances were measured between the centers of the 2 structures. Cross-sectional areas were computed by projecting points taken along the circumference of the attachment onto an interpolated plane and calculating the area of the resulting 2-dimensional (2D) polyhedron. Radiographic analysis was conducted by measuring the distances between marked anatomic sites on the AP and lateral views.

RESULTS

Qualitative Anatomy

All 4 medial patellar ligaments (MPFL, MPTL, MPML, MQTFL) were present in each of the 10 specimens. The MPFL's femoral attachment was consistently identified anterior and distal to the adductor tubercle. The femoral attachment had soft tissue attachments to the adductor magnus tendon. From this origin, it diverged deep to the VMO to attach broadly to the proximal third of the patella (MPFL) and to the deep layer of the quadriceps tendon (MQTFL) (Figure 1). The MPFL patellar attachment was at the superomedial aspect of the patella with a long, thin attachment adjacent to the quadriceps tendon and superficial to the patellar articular cartilage and joint capsule.

The MPML was consistently identified superficial and intimately adherent to the medial capsule. The MPML

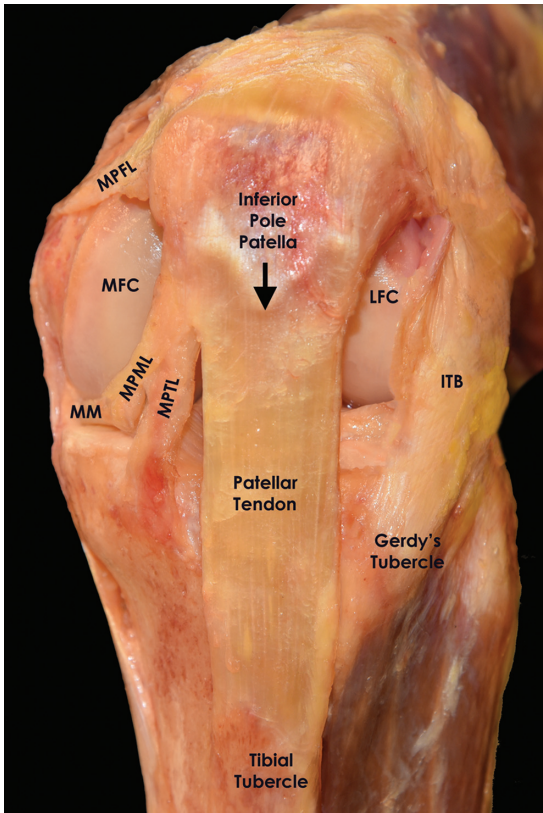


Figure 2. Anterior view of a left knee at 90° of flexion showing the attachments and orientations of the MPFL, MPTL, and MPML. ITB, iliotibial band; LFC, lateral femoral condyle; MFC, medial femoral condyle; MM, medial meniscus; MPFL, medial patellofemoral ligament; MPML, medial patellomeniscal ligament; MPTL, medial patellotibial ligament.

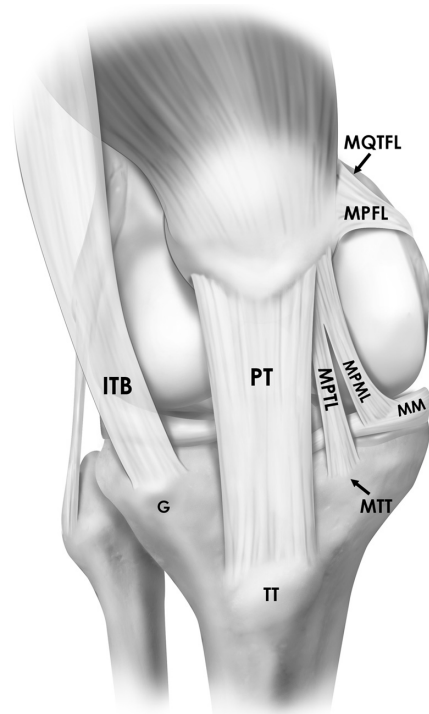


Figure 3. Illustration depicting the insertions and orientations of the medial patellar ligaments (MPFL, MPTL, MPML, MQTFL) on the femur, patella, tibia, and medial meniscus in a right knee from an anterior view. G, Gerdy tubercle; ITB, iliotibial band; MM, medial meniscus; MPFL, medial patellofemoral ligament; MPML, medial patellomeniscal ligament; MPTL, medial patellotibial ligament; MQTFL, medial quadriceps tendon femoral ligament; MTT, medial tibial tubercle; PT, patellar tendon; TT, tibial tubercle.

and MPTL shared a common insertion on the inferomedial patella, with a portion of the patellar attachment lying deep to the patellar tendon but superficial to the patellar articular cartilage and deeper joint capsule. After careful isolation of these structures, the MPTL coursed in a steep inferomedial orientation from its patellar attachment to insert on the anteromedial proximal tibia. The tibial insertion of the MPTL was located on a newly identified bony prominence, termed the *medial tibial tubercle*. The MPML traversed more horizontally than the MPTL (Figures 2 and 3) and was identified by its distinct distal attachment medial to the anterior horn of the medial meniscus (Figures 4 and 5). The MPTL was a thin, single-layer ligament, while the MPML was a round, cord-like ligament.

Quantitative Anatomy

MPFL Attachments. The MPFL attached near the superomedial pole of the patella with a mean insertion area of 37.6 mm². The MPFL patellar attachment center was located 17.9 mm proximal to the center of the MPTL/MPML patellar attachment (Figure 6). The distances

from the superior and inferior poles of the patella were 22.2 and 33.9 mm, respectively.

The femoral attachment of the MPFL was 14.9 mm from the medial epicondyle and 10.4 mm from the adductor tubercle. The mean area of the MPFL attachment on the distal femur was 26.0 mm². The MQTFL had a mean insertion length of 29.3 mm on the medial aspect of the distal quadriceps tendon. Additional MPFL-related measurements can be found in Tables 2 and 3.

MPTL Attachments. The proximal MPTL attachment, which shared a common insertion with the MPML, covered a mean area of 27.4 mm². The center of the patellar attachment was 3.5 mm medial and 3.5 mm proximal to the medial border of the patellar tendon attachment. The distances from the superior and inferior poles of the patella were 31.2 and 18.2 mm, respectively. The mean area of the MPTL attachment on the tibia was 46.3 mm². The mean angle orientation of the MPTL with respect to the patellar tendon was 8.3°. Additional MPTL-related measurements can be found in Tables 2 and 3.

MPML Attachments. The MPML shared a proximal attachment with the MPTL on the inferomedial aspect of the patella. The patellar attachment measurements are

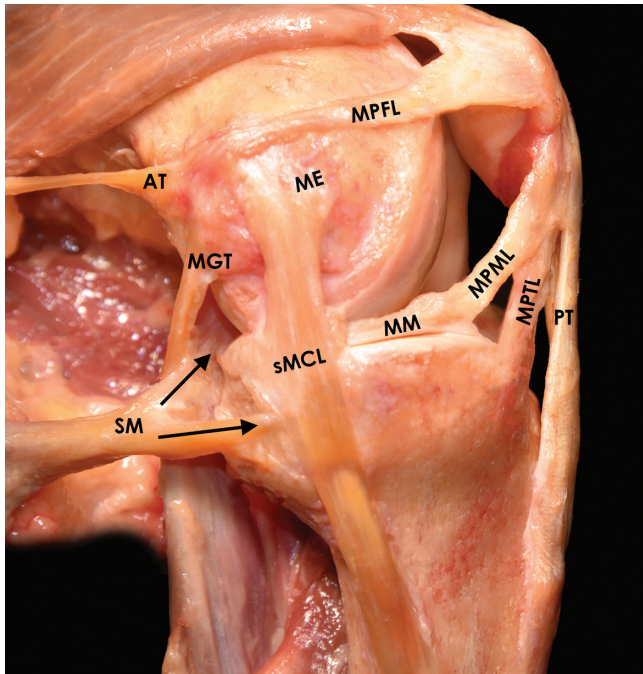


Figure 4. Medial view of a left knee at 90° of flexion demonstrating the attachment sites and orientations of the MPFL, MPTL, and MPML. The relationship of the medial patellar ligament’s attachment sites to other medial knee structures can also be appreciated. The arrows indicate the direct and indirect arms of the semimembranosus. AT, adductor tendon; ME, medial epicondyle; MGT, medial gastrocnemius tendon; MM, medial meniscus; MPFL, medial patellofemoral ligament; MPML, medial patellomeniscal ligament; MPTL, medial patellotibial ligament; PT, patellar tendon; SM, semimembranosus; sMCL, superficial medial collateral ligament.

the same as stated for the MPTL attachment. The MPML coursed just superficial to the capsule and attached 20.4 mm from the center of the anterior insertion of the medial meniscus with an average footprint of 38.4 mm². The mean angle orientation of the MPML with respect to the patellar tendon was 22.7° (Table 3). The MPML meniscal attachment was 12.0 mm proximal and 6.7 mm medial to the MPTL tibial attachment (Table 2).

Radiographic Measurements

Interrater reliability of individual radiograph examiners was assessed for each specimen. The interrater correlation coefficient was >0.75 (0.84-0.99) in all specimens, correlating to excellent agreement.

Patellar Attachments. On lateral radiographs, the center of the patellar insertion of the MPTL/MPML was 18.8 mm distal to the MPFL patellar attachment. Moreover, the MPTL/MPML insertion was 30.0 mm distal to the superior pole and 10.9 mm proximal to the inferior pole. Additional patellar- and structure-related attachment measurements can be found in Tables 4 and 5.

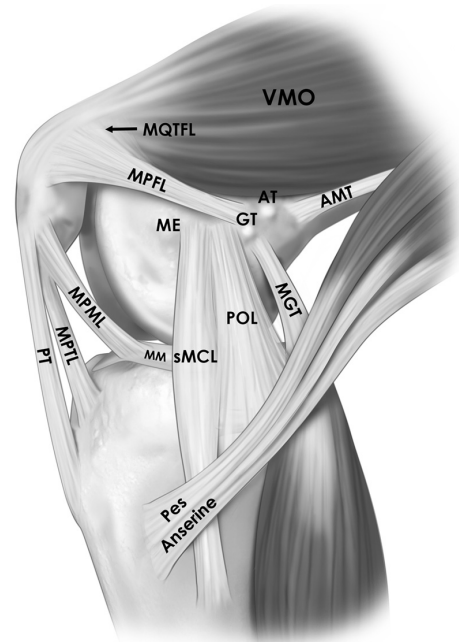


Figure 5. Illustration depicting the insertions of the medial patellar ligaments (MPFL, MPTL, MPML, MQTFL) on the femur, patella, tibia, and medial meniscus in a right knee. Note the relationship of the medial patellar ligaments with other anatomic structures of the medial knee. AMT, adductor magnus tendon; AT, adductor tubercle; GT, gastrocnemius tubercle; ME, medial epicondyle; MGT, medial gastrocnemius tendon; MM, medial meniscus; MPFL, medial patellofemoral ligament; MPML, medial patellomeniscal ligament; MPTL, medial patellotibial ligament; MQTFL, medial quadriceps tendon femoral ligament; POL, posterior oblique ligament; PT, patellar tendon; sMCL, superficial medial collateral ligament; VMO, vastus medialis oblique.

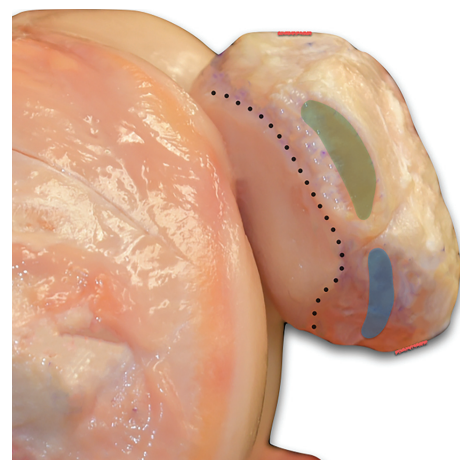


Figure 6. Medial view of a left knee showing the medial patellofemoral ligament (green) and the medial patellotibial ligament/medial patellomeniscal ligament (blue) patellar attachments in relation to the patellar articular cartilage (dotted line). The red lines indicate the approximate locations of the inferior and superior poles of the patella.

Tibial Attachments. On the AP radiographs, the center of the tibial insertion of the MPFL was 5.0 mm distal to the tibiofemoral joint line and 5.6 mm medial to the tibial center. Furthermore, the center of the MPFL attachment was 13.6 mm distal and 3.5 mm medial to the apex of the medial tibial eminence (Table 4).

On the lateral radiographs, the center of the tibial insertion of the MPFL was 9.3 mm distal to the tibial slope line and 16.2 mm anterior to the diaphyseal axis of the tibia (Table 5, Figure 7).

Femoral Attachments. On the AP radiographs, the center of the femoral insertion of the MPFL was 9.2 mm from the adductor tubercle, 3.5 mm from the gastrocnemius tubercle, 14.1 mm from the medial epicondyle, and 36.5 mm from the femoral condylar line (Table 4). On the lateral radiographs, the center of the femoral insertion of the MPFL was 9.7 mm from the adductor tubercle, 10.4 mm from the gastrocnemius tubercle, and 15.2 mm from the medial epicondyle. The attachment was also located 8.3 mm from the posterior femoral cortex extension line and 4.7 mm from a line perpendicular to the Blumensaat line (Table 5, Figure 7).

DISCUSSION

The most important findings of this study were that the MPFL, MPTL, MPML, and MQTFL were reproducibly quantified in relation to surrounding surgically relevant anatomic and osseous landmarks. In addition, a readily palpable bony ridge, which corresponded with the tibial insertion of the MPFL, was newly identified and termed the medial tibial tubercle. This detailed information is important in understanding patellofemoral joint pathology and can aid in treating patients with lateral patellar instability by allowing for more anatomic restoration of the medial patellar restraints. Furthermore, these anatomic relationships may be referenced intraoperatively and will be helpful in avoiding potential iatrogenic injuries during arthroscopic and open surgical approaches to the knee.

In the present study, the MPTL and MPML shared a common insertion on the distomedial patella with reproducible distances to pertinent osseous landmarks. Since the MPTL and MPML were first described by Slocum et al³¹ in 1974, several anatomic studies have attempted to define these medial patellar stabilizers.^{7,8,15,35,39} The current study also revealed the close proximity of the MPTL and MPML attachment to the patellar tendon and patellar articular cartilage, which has not been previously quantified. Furthermore, the tibial attachment of the MPTL was 5 mm distal to the joint line on plain radiographs, in contrast to the previously reported 10 to 20 mm.^{8,15,22} Given the close proximity to the articular cartilage of the patellar and tibial attachments, future reconstructions based on these landmarks should be supplemented with arthroscopy to ensure that the patellofemoral and tibiofemoral joint cartilage is not violated.

Given that the MPTL and MPML have been reported to be important for patella stability at higher flexion angles,²³ the ligament orientations with respect to the patellar tendon were obtained at 90° of knee flexion. The MPTL and MPML orientations relative to the patellar tendon were

8.3° and 22.7°, respectively. Panagiotopoulos et al²² described the MPTL (20°-25°) and MPML (15°-30°) to have very similar angles at 30° of knee flexion. Similarly, Kaleka et al¹⁵ reported a mean MPTL angle of 22.2° and an MPML angle of 24.2° relative to the patellar tendon at 20° to 30° of flexion. These angles are important intraoperatively, specifically for placement of the tibial anchor during a MPFL reconstruction.¹⁴ Thus, angles measured at lower degrees of flexion should be used with caution during reconstruction at higher flexion angles, because this may result in nonanatomic reconstructions. Additionally, the acute angle of the MPTL found in this study may place it at risk for iatrogenic injury with a horizontal anteromedial arthroscopic portal placement unless the portal is placed directly adjacent to the patellar tendon.

The function and injury patterns of the MPTL and MPML remain unclear. There is limited evidence of symptomatic knee dysfunction with isolated MPML injury.¹¹ However, magnetic resonance imaging studies have suggested that the MPTL is torn in most primary lateral patellar dislocations,³⁸ while others report injuries to the inferior portion of the medial retinaculum in the region corresponding to the MPTL/MPML in the absence of a patellar dislocation.³⁶ The biomechanical role of the MPTL and MPML in deep flexion needs further study to understand if and when they augment the prominent role of the bony trochlea in patella stabilization in deep flexion. Intuitively, these ligaments likely play a more dominant role when the trochlear sulcus is shallow throughout knee flexion. Future biomechanical and clinical studies are warranted to further elucidate the role and indications of MPTL and/or MPML reconstruction.

The findings of this study are similar to previous studies that qualitatively described the femoral attachment of the MPFL to be located between the adductor tubercle and medial epicondyle.^{7,8,22,24} A previous anatomic study evaluated the anatomy of the MPFL in 50 cadaveric specimens.³ In contrast to the current study, the author performed measurements with a ruler, which is less accurate than the ROMER arm utilized in the current study, and focused primarily on the widths along the length of the MPFL. However, that review does confirm the results of the present study in that the MPFL femoral attachment lies between the adductor tubercle and medial epicondyle and that the patellar attachments are on the superomedial aspect of the patella. Although the locations of the attachments were similar between studies, several qualitative descriptions differed. An inseparable attachment of the MPFL to the deep surface of the VMO and an oblique decussation originating from the proximal edge of the superficial medial collateral ligament were identified that were not described in the present study.

In the present study, the MPFL femoral insertion was 9.6 mm anterodistal to the adductor tubercle, 15.2 mm proximal and posterior to the medial epicondyle, 8.3 mm anterior to the posterior cortex extension line, and 4.7 mm proximal to the level of the posterior point of the Blumensaat line on lateral radiographs. These results are most comparable with an analysis of the medial knee anatomy by Wijdicks et al.⁴² Schöttle et al²⁸ and Stephen et al³²

TABLE 2
Mean Distance From the MPFL, MPTL, and MPML Attachments to Soft Tissue and Bony Landmarks^a

Landmark	Total			Anterior			Proximal			Lateral		
	Mean	Low CI	High CI	Mean	Low CI	High CI	Mean	Low CI	High CI	Mean	Low CI	High CI
Femur												
	Center of MPFL femoral attachment											
Medial epicondyle	14.9	12.1	17.8	2.1	0.3	3.9	-14.3	-17.4	-11.3	1.0	0.3	1.7
Adductor tubercle	10.4	8.7	12.1	-2.7	-5.0	-0.5	8.2	6.0	10.5	3.3	1.9	4.6
Gastrocnemius tubercle	11.1	9.0	13.3	-9.6	-11.8	-7.4	0.0	-3.1	3.2	2.2	1.1	3.4
Tibia												
	Center of MPTL tibial attachment											
Tibial tubercle	35.3	33.5	37.1	10.0	8.4	11.7	-24.5	-26.2	-22.9	23.0	21.2	24.9
Superficial MCL border	32.7	31.3	34.1	-24.6	-26.5	-22.8	-14.2	-16.9	-11.6	-15.2	-17.2	-13.3
Gerdy tubercle	47.4	44.1	50.6	-2.2	-5.1	0.8	-3.6	-8.4	1.1	46.4	43.0	49.7
Medial tibial tubercle	3.1	1.1	5.1	-0.2	-0.5	0.0	-2.6	-4.7	-0.5	-0.2	-1.0	0.5
MPML meniscal attachment	16.1	12.6	19.6	-7.0	-9.3	-4.7	12.0	10.4	13.5	-6.7	-10.4	-3.0
	Center of MPML meniscal attachment											
Center of anterior horn MM	20.4	17.9	22.9	4.7	2.8	6.6	-4.3	-6.3	-2.4	18.9	16.5	21.4
	Medial tibial tubercle											
Tibial tubercle	33.8	32.3	35.3	10.3	8.6	11.9	-21.9	-23.2	-20.6	23.2	21.1	25.4
Patella												
	Center of MPTL/MPML patellar attachment											
MPFL patellar center	19.0	17.2	20.9	2.1	0.8	3.4	17.9	16.2	19.6	-4.5	-6.9	-2.1
Inferior pole	18.2	15.2	21.2	0.4	-1.0	1.7	-9.1	-11.7	-6.5	15.4	13.2	17.7
Superior pole	31.2	29.5	33.0	0.4	-1.0	1.7	26.8	24.6	29.0	15.4	13.2	17.7
Medial patellar tendon point	6.3	4.8	7.8	0.4	-0.7	1.4	-3.5	-5.7	-1.4	3.5	1.7	5.2
Patella bone/cartilage line	9.4	7.5	11.3	-6.9	-8.1	-5.7	4.8	3.0	6.6	-2.9	-4.5	-1.4
	Center of MPFL patellar attachment											
Inferior pole	33.9	31.3	36.6	-1.7	-3.2	-0.3	-27.0	-30.5	-23.5	19.9	18.8	21.1
Superior pole	22.2	20.6	23.9	-1.7	-3.2	-0.3	8.9	6.5	11.3	19.9	18.8	21.1
Patella bone/cartilage line	5.8	4.7	6.8	-5.3	-6.4	-4.3	-1.0	-1.8	-0.1	0.2	-0.7	1.1
	MPFL patellar attachment closest to articular cartilage to patella bone/cartilage line											
	3.4	2.4	4.4	-2.9	-3.8	-1.9	-0.9	-1.6	-0.2	0.2	-0.6	1.0
	MPTL patellar attachment closest to articular cartilage to patella bone/cartilage line											
	6.3	4.9	7.7	-4.7	-5.8	-3.7	3.0	1.6	4.5	-1.7	-2.8	-0.7
	MPFL border closest to MPTL to MPTL border closest to MPFL											
	7.3	4.8	9.8	-1.0	-2.3	0.2	-6.7	-8.7	-4.6	1.5	-0.1	3.1
	Superior pole to inferior pole											
	35.9	33.9	37.9	0.0	0.0	0.0	-35.9	-37.9	-33.9	0.0	0.0	0.0

^aValues are in millimeters; “low CI” and “high CI” refer to the 95% CI. MCL, medial collateral ligament; MM, medial meniscus; MPFL, medial patellofemoral ligament; MPML, medial patellomeniscal ligament; MPTL, medial patellotibial ligament.

both described radiographic landmarks for femoral tunnel placement in MPFL reconstruction using different methods. Stephen et al³² theorized that the posterior cortex outline of the femur used by Schöttle et al²⁸ would lead to inconsistent placement of MPFL reconstruction tunnels. Instead, articular geometry and the size of the medial femoral condyle were utilized to determine the anatomic femoral attachment. The MPFL femoral location described from this study falls within Schöttle’s location but outside of Stephen’s point. The differences in tunnel position based on radiographs may be accounted for by slight variations in radiographic protocol and technique. As Ziegler et al⁴⁴ recently reported, positioning even 5° off-axis from a true lateral radiograph has a significant effect on the radiographic positioning of the MPFL femoral tunnel. Although Schöttle’s and Stephen’s points are both utilized for MPFL reconstruction, neither has allowed for precise anatomic femoral placement.²⁷

In addition to the femoral and patellar attachments, the MPFL had an extension attaching to the quadriceps

tendon, known as the MQTFL. There has been increasing focus on the attachment of the MPFL to the quadriceps tendon,^{33,34} including Mochizuki et al,²⁰ who reported quantitative results comparable to our study. Similar to the biomechanical investigations into the role of the VMO,²² studies need to be performed to elucidate the biomechanical role of the MQTFL as a potential dynamic stabilizer of the patella. Reconstruction techniques have attempted to replicate the MQTFL by suturing a graft to the quadriceps tendon¹⁰ or by utilizing a section of the quadriceps tendon to reconstruct the MPFL.¹² The latter has shown outcomes comparable to those of other studies that used hamstring grafts but without associated patellar complications.¹²

Limitations in the present study include those inherent to a cadaveric study design. Radiographic measurements provided 2D distances between structures, which may have resulted in an underestimation of the true 3D distance. However, 3D distances were also calculated according to the 3D coordinate-measuring device, and the 2 measurements

TABLE 3
Mean Insertional Areas and Ligament Lengths of the MPFL, MPTL, and MPML^a

	Mean	Low CI	High CI
Areas, mm ²			
MPFL femoral attachment	25.9	22.7	29.2
MPFL patellar attachment	37.6	26.0	49.2
MPTL/MPML patellar attachment	27.4	19.7	35.1
MPTL tibial attachment	46.3	34.6	58.0
MPML meniscal attachment	38.4	31.5	45.2
Approximate ligament length, mm			
MPFL	56.5	54.2	58.8
MPTL	44.3	40.7	48.0
MPML	34.7	31.2	38.2
Angle of orientation, deg			
MPTL to patellar tendon	8.3	5.7	10.9
MPML to patellar tendon	22.7	15.3	30.0
MQTFL insertion length, mm	29.3	28.0	30.6

^aMean angles of orientation (degrees) of the MPTL and MPML are also reported, as well as the mean MQTFL insertion length on the medial aspect of the distal quadriceps tendon. “Low CI” and “high CI” refer to the 95% CI. MPFL, medial patellofemoral ligament; MPML, medial patellomeniscal ligament; MPTL, medial patellotibial ligament; MQTFL, medial quadriceps tendon femoral ligament.

TABLE 5
Lateral Radiographic View^a

	Mean Distance (95% CI), mm	Directionality
MPTL/MPML patellar attachment from		
Superior pole	30.0 (28.3-31.8)	Distal
Inferior pole	10.9 (8.8-13.1)	Proximal
MPFL insertion	18.8 (16.4-21.1)	Distal
Most distal cartilage	10.0 (7.5-12.6)	Proximal
	6.1 (4.5-7.6)	Anterior
MPFL patellar insertion from		
Superior pole	11.9 (9.2-14.7)	Distal
Inferior pole	29.3 (26.0-32.7)	Proximal
Most distal cartilage	26.5 (26.2-32.8)	Proximal
	5.0 (3.4-6.6)	Anterior
MPTL tibial attachment from		
Tibial tubercle	28.5 (26.3-30.7)	Proximal
	5.6 (4.3-6.9)	Posterior
Tibial slope line	9.3 (6.9-11.6)	Distal
Diaphyseal axis of tibia	16.2 (13.6-18.7)	Anterior
MPFL femoral attachment from		
Adductor tubercle	9.7 (8.6-10.8)	Distal
Gastrocnemius tubercle	10.4 (7.9-12.9)	Anterior
Medial epicondyle	15.2 (12.8-17.6)	Proximal
Posterior femoral cortex extension line	8.3 (5.1-11.5)	Anterior
Perpendicular line to Blumensaat line	4.7 (2.4-6.9)	Proximal

^aRadiographic measurements of the distances (mm) between the medial patellar ligament footprints and pertinent osseous landmarks on the tibia and femur on lateral view. MPFL, medial patellofemoral ligament; MPML, medial patellomeniscal ligament; MPTL, medial patellotibial ligament.

TABLE 4
Anteroposterior Radiographic View^a

	Mean Distance (95% CI), mm	Directionality
MPTL tibial attachment from		
Tibiofemoral joint line	5.0 (3.2-6.8)	Distal
Tibial center	5.6 (3.4-7.9)	Medial
Medial tibial eminence	13.6 (11.7-15.4)	Distal
	3.5 (2.3-4.7)	Medial
MPFL femoral attachment from		
Adductor tubercle	9.2 (7.8-10.6)	Distal
Gastrocnemius tubercle	3.5 (2.3-4.6)	Proximal
Medial epicondyle	14.1 (10.8-17.5)	Proximal
Femoral condylar line	36.5 (34.7-38.2)	Proximal

^aRadiographic measurements of the distances (mm) between ligament footprints and pertinent anatomic osseous landmarks on the femur on anteroposterior view. MPFL, medial patellofemoral ligament; MPTL, medial patellotibial ligament.

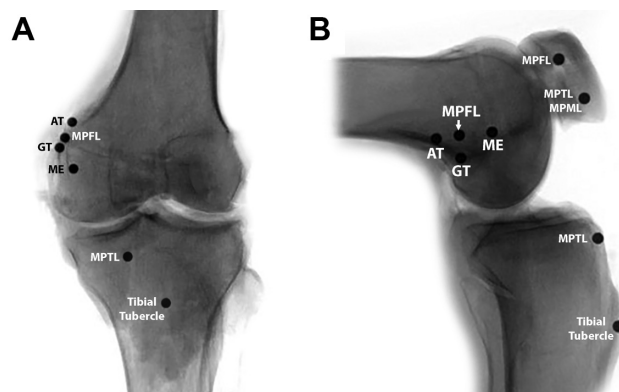


Figure 7. (A) Anteroposterior and (B) lateral radiographic views of a left knee demonstrating the positioning of the spherical markers and their relationship to surgically relevant landmarks. AT, adductor tubercle; GT, gastrocnemius tubercle; ME, medial epicondyle; MPFL, medial patellofemoral ligament; MPML, medial patellomeniscal ligament; MPTL, medial patellotibial ligament.

were compared to ensure accuracy. Finally, the 90° of knee flexion utilized during quantitative data collection—although consistent with the reported degree of knee flexion at which the MPTL and MPML are more important biomechanically—limits the utilization of data at other flexion angles owing to the possible distortion of the anatomic relationships.

CONCLUSION

The most important findings of this study were the correlative anatomy of 4 distinct medial patellar ligaments (MPFL, MPTL, MPML, MQTFL), as well as the identification of a bony ridge on the medial proximal tibia that consistently served as the attachment site for the MPTL. The quantitative and radiographic measurements, while

comparable with current literature, detailed the meniscal insertion of the MPML and defined a patellar insertion of the MPPL and the MPML as a single attachment. The data allow for reproducible landmarks to be established from previously known bony and soft tissue structures.

REFERENCES

- Arendt EA, Fithian DC, Cohen E. Current concepts of lateral patella dislocation. *Clin Sports Med*. 2002;21(3):499-519.
- Askenberger M, Arendt EA, Ekstrom W, Voss U, Finnbogason T, Janarv PM. Medial patellofemoral ligament injuries in children with first-time lateral patellar dislocations: a magnetic resonance imaging and arthroscopic study. *Am J Sports Med*. 2016;44(1):152-158.
- Baldwin JL. The anatomy of the medial patellofemoral ligament. *Am J Sports Med*. 2009;37(12):2355-2361.
- Bitar AC, Demange MK, D'Elia CO, Camanho GL. Traumatic patellar dislocation: nonoperative treatment compared with MPFL reconstruction using patellar tendon. *Am J Sports Med*. 2012;40(1):114-122.
- Camanho GL, Viegas Ade C, Bitar AC, Demange MK, Hernandez AJ. Conservative versus surgical treatment for repair of the medial patellofemoral ligament in acute dislocations of the patella. *Arthroscopy*. 2009;25(6):620-625.
- Cofield RH, Bryan RS. Acute dislocation of the patella: results of conservative treatment. *J Trauma*. 1977;17(7):526-531.
- Conlan T, Garth WP Jr, Lemons JE. Evaluation of the medial soft-tissue restraints of the extensor mechanism of the knee. *J Bone Joint Surg Am*. 1993;75(5):682-693.
- Desio SM, Burks RT, Bachus KN. Soft tissue restraints to lateral patellar translation in the human knee. *Am J Sports Med*. 1998;26(1):59-65.
- Fleiss J. *The Design and Analysis of Clinical Experiments*. New York, NY: Wiley; 1986.
- Fulkerson JP, Edgar C. Medial quadriceps tendon-femoral ligament: surgical anatomy and reconstruction technique to prevent patella instability. *Arthrosc Tech*. 2013;2(2):E125-E128.
- Garth WP Jr, Connor GS, Futch L, Belarmino H. Patellar subluxation at terminal knee extension: isolated deficiency of the medial patello-meniscal ligament. *J Bone Joint Surg Am*. 2011;93(10):954-962.
- Goyal D. Medial patellofemoral ligament reconstruction: the superficial quad technique. *Am J Sports Med*. 2013;41(5):1022-1029.
- Grood ES, Suntay WJ. A joint coordinate system for the clinical description of three-dimensional motions: application to the knee. *J Biomech Eng*. 1983;105(2):136-144.
- Hinckel BB, Gobbi RG, Demange MK, Bonadio MB, Pecora JR, Camanho GL. Combined reconstruction of the medial patellofemoral ligament with quadriceps tendon and the medial patellofemoral ligament with patellar tendon. *Arthrosc Tech*. 2016;5(1):E79-E84.
- Kaleka CC, Aihara LJ, Rodrigues A, de Medeiros SF, de Oliveira VM, de Paula Leite Cury R. Cadaveric study of the secondary medial patellar restraints: patellofemoral and patellofemoral ligaments. *Knee Surg Sports Traumatol Arthrosc*. 2017;25(1):144-151.
- Kennedy MI, Claes S, Fuso FA, et al. The anterolateral ligament: an anatomic, radiographic, and biomechanical analysis. *Am J Sports Med*. 2015;43(7):1606-1615.
- Maenpaa H, Lehto MU. Patellofemoral osteoarthritis after patellar dislocation. *Clin Orthop Relat Res*. 1997;339:156-162.
- Mazzuca SA, Brandt KD, Dieppe PA, Doherty M, Katz BP, Lane KA. Effect of alignment of the medial tibial plateau and x-ray beam on apparent progression of osteoarthritis in the standing anteroposterior knee radiograph. *Arthritis Rheum*. 2001;44(8):1786-1794.
- Mehta VM, Inoue M, Nomura E, Fithian DC. An algorithm guiding the evaluation and treatment of acute primary patellar dislocations. *Sports Med Arthrosc*. 2007;15(2):78-81.
- Mochizuki T, Nimura A, Tateishi T, Yamaguchi K, Muneta T, Akita K. Anatomic study of the attachment of the medial patellofemoral ligament and its characteristic relationships to the vastus intermedius. *Knee Surg Sports Traumatol Arthrosc*. 2013;21(2):305-310.
- Nomura E, Horiuchi Y, Kihara M. Medial patellofemoral ligament restraint in lateral patellar translation and reconstruction. *Knee*. 2000;7(2):121-127.
- Panagiotopoulos E, Strzelczyk P, Herrmann M, Scuderi G. Cadaveric study on static medial patellar stabilizers: the dynamizing role of the vastus medialis obliquus on medial patellofemoral ligament. *Knee Surg Sports Traumatol Arthrosc*. 2006;14(1):7-12.
- Philippot R, Boyer B, Testa R, Farizon F, Moyon B. The role of the medial ligamentous structures on patellar tracking during knee flexion. *Knee Surg Sports Traumatol Arthrosc*. 2012;20(2):331-336.
- Philippot R, Chouteau J, Wegrzyn J, Testa R, Fessy MH, Moyon B. Medial patellofemoral ligament anatomy: implications for its surgical reconstruction. *Knee Surg Sports Traumatol Arthrosc*. 2009;17(5):475-479.
- Pietrini SD, LaPrade RF, Griffith CJ, Wijdicks CA, Ziegler CG. Radiographic identification of the primary posterolateral knee structures. *Am J Sports Med*. 2009;37(3):542-551.
- Sallay PI, Poggi J, Speer KP, Garrett WE. Acute dislocation of the patella: a correlative pathoanatomic study. *Am J Sports Med*. 1996;24(1):52-60.
- Sanchis-Alfonso V, Ramirez-Fuentes C, Montesinos-Berry E, Aparisi-Rodriguez F, Marti-Bonmati L. Does radiographic location ensure precise anatomic location of the femoral fixation site in medial patellofemoral ligament surgery? *Knee Surg Sports Traumatol Arthrosc*. 2016;24(9):2838-2844.
- Schöttle PB, Schmeling A, Rosenstiel N, Weiler A. Radiographic landmarks for femoral tunnel placement in medial patellofemoral ligament reconstruction. *Am J Sports Med*. 2007;35(5):801-804.
- Shah JN, Howard JS, Flanigan DC, Brophy RH, Carey JL, Lattermann C. A systematic review of complications and failures associated with medial patellofemoral ligament reconstruction for recurrent patellar dislocation. *Am J Sports Med*. 2012;40(8):1916-1923.
- Sillanpaa PJ, Peltola E, Mattila VM, Kiuru M, Visuri T, Pihlajamaki H. Femoral avulsion of the medial patellofemoral ligament after primary traumatic patellar dislocation predicts subsequent instability in men: a mean 7-year nonoperative follow-up study. *Am J Sports Med*. 2009;37(8):1513-1521.
- Slocum DB, Larson RL, James SL. Late reconstruction of ligamentous injuries of the medial compartment of the knee. *Clin Orthop Relat Res*. 1974;100:23-55.
- Stephen JM, Lumpaopong P, Deehan DJ, Kader D, Amis AA. The medial patellofemoral ligament: location of femoral attachment and length change patterns resulting from anatomic and nonanatomic attachments. *Am J Sports Med*. 2012;40(8):1871-1879.
- Tanaka MJ. Variability in the patellar attachment of the medial patellofemoral ligament. *Arthroscopy*. 2016;32(8):1667-1670.
- Tanaka MJ, Voss A, Fulkerson JP. The anatomic midpoint of the attachment of the medial patellofemoral complex. *J Bone Joint Surg Am*. 2016;98(14):1199-1205.
- Terry GC. The anatomy of the extensor mechanism. *Clin Sports Med*. 1989;8(2):163-177.
- Thawait SK, Soldatos T, Thawait GK, Cosgarea AJ, Carrino JA, Chhabra A. High resolution magnetic resonance imaging of the patellar retinaculum: normal anatomy, common injury patterns, and pathologies. *Skeletal Radiol*. 2012;41(2):137-148.
- Tompkins MA, Arendt EA. Patellar instability factors in isolated medial patellofemoral ligament reconstructions—what does the literature tell us? A systematic review. *Am J Sports Med*. 2015;43(9):2318-2327.
- Tompkins MA, Rohr SR, Agel J, Arendt EA. Anatomic patellar instability risk factors in primary lateral patellar dislocations do not predict injury patterns: an MRI-based study [published online February 28, 2017]. *Knee Surg Sports Traumatol Arthrosc*. doi:10.1007/s00167-017-4464-3

39. Tuxoe JI, Teir M, Winge S, Nielsen PL. The medial patellofemoral ligament: a dissection study. *Knee Surg Sports Traumatol Arthrosc.* 2002;10(3):138-140.
40. Weber AE, Nathani A, Dines JS, et al. An algorithmic approach to the management of recurrent lateral patellar dislocation. *J Bone Joint Surg Am.* 2016;98(5):417-427.
41. Weber-Spickschen TS, Spang J, Kohn L, Imhoff AB, Schöttle PB. The relationship between trochlear dysplasia and medial patellofemoral ligament rupture location after patellar dislocation: an MRI evaluation. *Knee.* 2011;18(3):185-188.
42. Wijdicks CA, Griffith CJ, LaPrade RF, et al. Radiographic identification of the primary medial knee structures. *J Bone Joint Surg Am.* 2009;91(3):521-529.
43. Wu G, Cavanagh PR. ISB recommendations for standardization in the reporting of kinematic data. *J Biomech.* 1995;28(10):1257-1261.
44. Ziegler CG, Fulkerson JP, Edgar C. Radiographic reference points are inaccurate with and without a true lateral radiograph: the importance of anatomy in medial patellofemoral ligament reconstruction. *Am J Sports Med.* 2016;44(1):133-142.

For reprints and permission queries, please visit SAGE's Web site at <http://www.sagepub.com/journalsPermissions.nav>.