

Quantitative and Qualitative Assessment of Posterolateral Meniscal Anatomy

Defining the Popliteal Hiatus, Popliteomeniscal Fascicles, and the Lateral Meniscotibial Ligament

Zachary S. Aman,[†] BA, Nicholas N. DePhillipo,^{*§} MS, ATC, OTC, Hunter W. Storaci,[†] MSc, Gilbert Moatshe,^{†‡} MD, PhD, Jorge Chahla,[†] MD, PhD, Lars Engebretsen,^{‡§} MD, PhD, and Robert F. LaPrade,^{*||} MD, PhD
Investigation performed at the Department of Biomedical Engineering, Steadman Philippon Research Institute, Vail, Colorado, USA

Background: Surgical treatment of lateral meniscal tears can be challenging due to the greater mobility of the lateral meniscus, thin capsule, and management of the popliteal hiatus. There has been a lack of quantitative assessments of the structural attachments to the posterior horn of the lateral meniscus (PHLM) to guide repairs.

Purpose: To qualitatively and quantitatively describe the anatomy of the PHLM, popliteomeniscal fascicles, and the posterolateral capsule.

Study Design: Descriptive laboratory study.

Methods: Fourteen male, nonpaired, fresh-frozen cadaveric knees were used. The attachments of the posterolateral capsule, popliteomeniscal fascicles, and meniscofemoral ligaments to the lateral meniscus and the attachment of the meniscotibial ligament to the tibia were identified. A 3-dimensional coordinate measuring system was used to measure the relationships of these attachments to surgically relevant landmarks and their structural relationship with the lateral meniscus.

Results: The posterolateral capsule attachment had a confluent attachment at the superior margin of the PHLM, quantitatively attaching to the proximal 11% of the total height of the PHLM. On average, the length of the posterolateral capsule attachment to the superior surface of the PHLM was 16.7 ± 2.7 mm. The average length of the meniscotibial attachment to the posteroinferior aspect of the meniscus was 12.8 ± 3.9 mm. There was a lack of ligamentous attachments to the lateral meniscus between the lateral aspect of the meniscotibial ligament and the anterior aspect of the anterosuperior popliteomeniscal fascicle, where only popliteomeniscal fascicle and capsular attachments to the posterior meniscus were present.

Conclusion: This anatomic study provides quantitative guidelines for the complex attachments to the PHLM. Knowledge of the quantitative descriptions of these attachments may aid in an improved intraoperative diagnosis of PHLM tears that extend to the popliteal hiatus, and further studies related to the surgical repair of the intricate attachments to the PHLM are recommended.

Clinical Relevance: The findings of this study provide the anatomic foundation for an improved understanding of the role of the meniscocapsular, meniscotibial, and popliteomeniscal fascicle attachments of the posterolateral meniscus. Understanding the differences between the lengths of the superior and inferior aspects of the popliteal hiatus will help to further refine characterization of tears extending into the popliteal hiatus and to avoid potential overconstraint of the more mobile lateral meniscus during a repair by anatomically reproducing its native structural attachments.

Keywords: knee; lateral meniscus; quantitative anatomy; meniscotibial; popliteomeniscal; posterolateral capsule

The structure and function of the lateral meniscus has been well described, yet surgical treatment of the posterior horn of the lateral meniscus (PHLM) tears remains challenging. This is in part due to the greater mobility of the

lateral meniscus in comparison with the medial meniscus, its thin and loose posterior capsule, and the interruption of its capsular attachments at the popliteal hiatus.^{1,19,27} In particular, higher failure rates for lateral meniscal repairs have been reported in patients with tears in the popliteal hiatal region,^{10,15,25} which has been suggested to be attributable to low vascularity in this area.^{3,10}

The popliteomeniscal fascicles (anteroinferior, posterosuperior, and posteroinferior) have been reported to have a role in rotational knee stability,^{7,18,20,21,23} and injuries to

these structures often occur concomitantly with anterior cruciate ligament and posterolateral corner injuries. Injury to the attachments to the PHLM have been reported to result in meniscal hypermobility and subluxation.¹¹ However, these injuries have been reported to often go unrecognized due to their commonly reported normal appearances on magnetic resonance imaging (MRI) or the lack of arthroscopic visualization.^{1,4,11,13,18,24} Therefore, awareness of these injuries and a thorough understanding of the anatomy and relationships of the PHLM structural attachments are important when managing patients with lateral meniscal tears, hypermobility, and subluxation.

Although the qualitative anatomy of the PHLM has been previously described, there has been a lack of quantitative assessments of the structural attachments to the lateral meniscus. Therefore, the purpose of this study was to qualitatively and quantitatively describe the anatomy of the PHLM, popliteomeniscal fascicles, and the posterolateral capsule. It was hypothesized that these structures would have definable attachments and consistent relationships with one another and surgically relevant landmarks.

METHODS

Specimen Preparation

Fourteen nonpaired, fresh-frozen male cadaveric knee specimens (mean age, 61.0 years; range, 54-66 years) with no evidence of meniscal or ligamentous defect, previous surgery, or osteoarthritis were used for this study. The cadaveric specimens utilized in this study were donated to a tissue bank for the purpose of medical research and then purchased by our institution. The use of cadaveric specimens is exempt at the authors' institution, so institutional review board approval was not required.

Before testing, a lateral parapatellar arthrotomy was performed on each specimen to check for intra-articular defect including lateral meniscal damage and no significant macroscopic osteoarthritic changes of the tibial plateau. Screened knees were then dissected of all skin and subcutaneous tissue, and all muscle tissue was removed with the exception of the popliteal muscle and tendon and the fibular collateral ligament. Further dissection was carried down to the posterolateral capsule, ensuring that all posterolateral capsular and stabilizing structures were left intact. The tibia, fibula, and femur were then cut 14 cm from the joint line. The tibia and fibula were then fixed in anatomic position and potted in a cylindrical mold of poly(methyl methacrylate) (Fricke Dental International Inc). A sagittal saw cut

through the trochlear arch point² and midline of the femur was then performed to allow direct visualization of the PHLM, while ensuring that the femoral attachments of the posterolateral capsule, fibular collateral ligament, and popliteal tendon were left intact.

Anatomic Measurements

The potted distal end of the knee was rigidly clamped to a testing table and pins were inserted into the lateral meniscal tissue to prevent any motion during data collection. Data points of interest were collected with a coordinate measuring device (manufacturer-reported repeatability of 0.025 mm) (Romer Absolute Arm; Hexagon Metrology) and recorded using Rhino 5 software (McNeel North America). A coordinate system was then developed using the knee's main axes. The proximal-distal direction was defined using the tibial axis. The medial-lateral direction was defined by points on the most medial and lateral aspects of the tibial plateaus. The anterior-posterior axis was calculated as the vector perpendicular to the coronal plane, which was defined by the proximal-distal and medial-lateral axes. A single investigator (N.N.D.) obtained all data points of interest for all specimens to reduce interobserver variability. A board-certified orthopaedic surgeon (G.M.) was present to validate structural landmarks throughout data collection. The 3-dimensional data points were then imported into Python software (Python Software Foundation, <https://www.python.org>) and a custom software program was used to calculate the desired measurements.¹⁷

Landmarks and Measurements

Continuous measurement points along the periphery of the lateral meniscus were taken from the posterior root to the anterior root attachments, and the total lateral meniscal length was calculated by summing the distances between each point. Attachment points were reported as a percentage of the entire lateral meniscal length and as curved distances from the center of the posterior root attachment. Curved distances were calculated by summing the 3-dimensional distances along the peripheral points of the lateral meniscus to the point of interest.

The length of the PHLM was measured along the periphery of the meniscus using 5 data points. Corresponding to these points, additional points from the most medial posterior attachment to the posterior margin of the popliteal hiatus were taken to calculate the posterolateral capsular attachment length. The length of the popliteal

^{||}Address correspondence to Robert F. LaPrade, MD, PhD, Twin Cities Orthopedics, 4010 West 65th Street, Edina, MN 55435, USA (email: laprademdphd@gmail.com).

*The Steadman Clinic, Vail, Colorado, USA.

[†]Steadman Philippon Research Institute, Vail, Colorado, USA.

[‡]University of Oslo, Oslo University Hospital, Oslo, Norway.

[§]Oslo Sports Trauma Research Center, Department of Sports Medicine, Norwegian School of Sport Sciences, Oslo, Norway.

One or more of the authors has declared the following potential conflict of interest or source of funding: R.F.L. receives royalties from Arthrex and Smith & Nephew; is a paid consultant for Arthrex, Ossur, and Smith & Nephew; and receives research support from Arthrex, Linvatec, Ossur, and Smith & Nephew. AOSSM checks author disclosures against the Open Payments Database (OPD). AOSSM has not conducted an independent investigation on the OPD and disclaims any liability or responsibility relating thereto.

TABLE 1
Average Dimensions of the Lateral Meniscus and Lateral Tibial Plateau (n = 14)^a

Structure	Distance (Mean ± SD), mm
Anterior horn LM width	7.5 ± 1.5
Midbody LM width	10.4 ± 1.9
Posterior horn LM width	10.4 ± 1.5
Height of posterior LM	4.7 ± 1.5
Length of lateral tibial plateau	42.9 ± 2.4
Width of lateral tibial plateau	35.1 ± 3.6
Total length of LM	93.7 ± 8.5

^aLM, lateral meniscus.

hiatus was measured along the superior periphery of the meniscus using 3 points starting at the posterior margin attachment and ending at the anterior margin attachment. Further dissection was then performed to identify the popliteomeniscal fascicle attachments to the lateral meniscus or tibia (for the posteroinferior popliteomeniscal fascicle). Once identified, the lengths of the anteroinferior, posterosuperior, and posteroinferior popliteomeniscal attachments were measured by summing the distances of 3 recorded data points for each structure. The attachment midpoints of the anterior and posterior meniscofemoral ligaments to the PHLM were recorded using 1 data point each.

Each structure of interest was evaluated to assess its distance to surgically relevant landmarks. Surgically relevant landmarks included the tibial articular cartilage posterior and distal margin, the lateral tibial eminence, the center of the posterolateral meniscal root attachment, and the center of the posterior cruciate ligament tibial attachment. Finally, digital calipers (manufacturer-reported accuracy of ±0.02) (Fowler High Precision) were used to measure the height and width of the anterior horn, midbody, and PHLM, and the length and width of the lateral tibial plateau.

RESULTS

PHLM Meniscocapsular and Meniscotibial Ligament Attachments

The average length of the superior aspect of the PHLM, defined as the distance from the edge of the posterior root of the lateral meniscus to the most medial aspect of the posterosuperior popliteomeniscal fascicle, was 23.1 ± 4.6 mm. The posterolateral capsule attachment had a confluent attachment at the superior margin of the PHLM, quantitatively attaching to the proximal 11% of the total height of the PHLM and 7.6 ± 2.5 mm superior to the tibial articular cartilage margin. The average length of the posterolateral capsule attachment to the superior aspect of the PHLM was 16.7 ± 2.7 mm (Figure 1). The average length of the meniscotibial attachment to the posteroinferior aspect of the lateral meniscus was 12.8 ± 3.9 mm. The curved distance from the most medial point of the meniscotibial ligament attachment to the center of the posterior root of the lateral meniscus was 6.0 ± 3.0 mm. Dimensions of the lateral tibial plateau and lateral meniscus are summarized in Table 1.

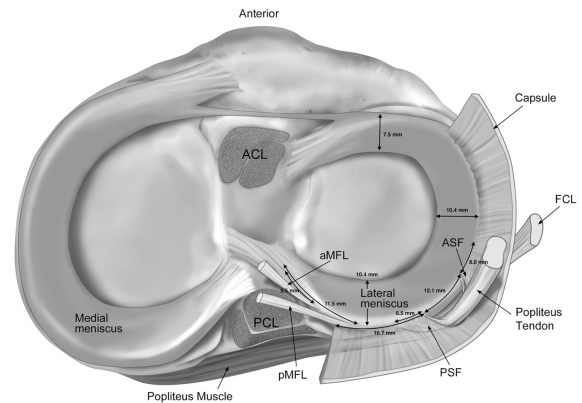


Figure 1. Axial view illustration of the anatomic relationships of the posterolateral meniscus, lateral capsule, popliteal tendon, anterior meniscofemoral ligament (aMFL), posterior meniscofemoral ligament (pMFL), anterosuperior popliteomeniscal fascicle (ASF), and posterosuperior popliteomeniscal fascicle (PSF). ACL, anterior cruciate ligament; FCL, fibular collateral ligament; PCL, posterior cruciate ligament.

Popliteal Hiatus

The total average length of the superior aspect of the popliteal hiatus was 12.1 ± 2.5 mm. The posterior and anterior margins of the superior popliteal hiatal attachments to the lateral meniscus corresponded to 36.0% and 48.6% of the total length of the lateral meniscus with respect to the posterior root attachment. On an average curved distance along the superior periphery of the lateral meniscus, the popliteal hiatus began 33.6 ± 3.7 mm from the center of the posterolateral meniscal root attachment. Qualitatively, there was a lack of ligamentous attachments to the inferior margin of the lateral meniscus between the lateral extent of the meniscotibial ligament and the most anterior aspect of the anterosuperior popliteomeniscal fascicle, where only popliteomeniscal fascicle and capsular attachments to the posterior meniscus were observed. We defined this gap as the inferior popliteal hiatus, and its curved length was 36.9 ± 6.0 mm (Figures 2 and 3). On average, the inferior popliteal hiatus began 22.8 ± 4.2 mm from the center of the posterolateral meniscal root attachment.

Popliteomeniscal Fascicle Attachments

Three stout attachments to the lateral meniscus were identified emerging from the popliteus tendon: the anterosuperior, posterosuperior, and posteroinferior popliteomeniscal fascicles (Figure 4). The anterosuperior and posteroinferior popliteomeniscal fascicles were identified in 100% of specimens, while the posterosuperior popliteomeniscal fascicle was identified in 13 of 14 specimens (92.8%). The average lengths of the anterosuperior, posterosuperior, and posteroinferior popliteomeniscal fascicle attachments to the lateral meniscus were 8.0 ± 1.9 mm, 6.5 ± 1.5 mm, and 8.5 ± 1.8 mm, respectively. The anterosuperior, posterosuperior, and posteroinferior popliteomeniscal fascicle

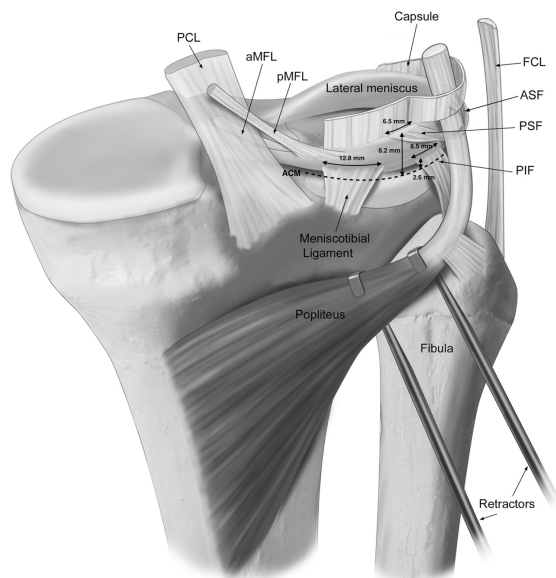


Figure 2. Posteromedial view illustration of the anatomic attachments to the posterolateral meniscus. The inferior extensions of the posterior capsule were removed and the popliteal tendon was reflected to visualize the underlying structural attachments of the meniscotibial ligament and the popliteomeniscal fascicles. ACM, tibial articular cartilage margin; aMFL, anterior meniscofemoral ligament; ASF, antero-superior popliteomeniscal fascicle; FCL, fibular collateral ligament; PCL, posterior cruciate ligament; PIF, posteroinferior popliteomeniscal fascicle; pMFL, posterior meniscofemoral ligament; PSF, posterosuperior popliteomeniscal fascicle.

attachments on the lateral meniscus were 4.6 ± 2.3 mm, 6.19 ± 1.9 mm, and 2.6 ± 2.3 mm superior to the tibial articular cartilage margin, respectively.

Meniscofemoral Ligament Attachments to Lateral Meniscus

The anterior meniscofemoral ligament (aMFL) (ligament of Humphrey) was identified in 9 of the 14 specimens (64%), while the posterior meniscofemoral ligament (pMFL) (ligament of Wrisberg) was identified in all specimens. The relationships of the anterior and posterior meniscofemoral ligaments to surgically relevant landmarks are summarized in Table 2. The distances between the aMFL and pMFL attachments to the lateral meniscus and the center of the posterior root of the lateral meniscus were 5.5 ± 2.9 mm and 11.5 ± 4.4 mm, respectively.

DISCUSSION

The most important finding of this study was that we were able to reproducibly identify and qualitatively and quantitatively describe the unique structural attachments of the 3 popliteomeniscal fascicles, posterolateral capsule, meniscotibial ligament, and the meniscofemoral ligaments to the

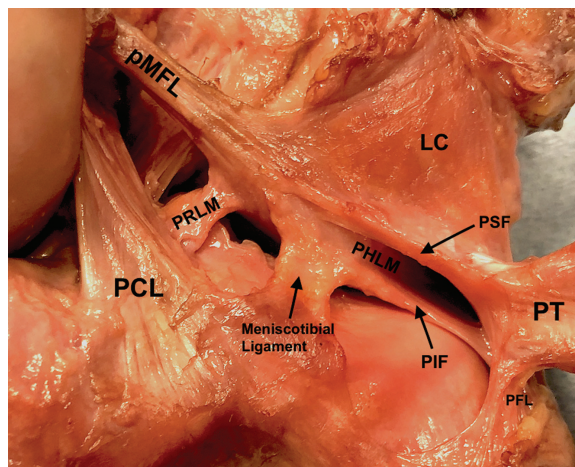


Figure 3. Posteromedial view photograph of the anatomic attachments to the posterolateral meniscus in a right knee. LC, lateral capsule; PCL, posterior cruciate ligament; PFL, popliteofibular ligament; PHLM, posterior horn of the lateral meniscus; PIF, posteroinferior popliteomeniscal fascicle; pMFL, posterior meniscofemoral ligament; PRLM, posterior root of the lateral meniscus; PSF, posterosuperior popliteomeniscal fascicle; PT, popliteal tendon.

posterolateral meniscus. Most notably, this study quantified the dimensions of the popliteal hiatus, while also highlighting a region of the posterior meniscus that is only restrained by capsular or popliteomeniscal fascicle attachments. The findings of this study provide the anatomic foundation for an improved understanding of the role of the meniscocapsular, meniscotibial, and popliteomeniscal fascicle attachments of the posterior aspect of the lateral meniscus. Understanding the differences between the lengths of the superior and inferior aspects of the popliteal hiatus will help to further refine characterization of tears extending into the popliteal hiatus and to avoid potential overconstraint of the more mobile lateral meniscus during a repair by anatomically reproducing its native structural attachments.

Previous studies have reported that the lateral meniscus has significantly more anteroposterior excursion than the medial meniscus.²⁶ In comparison with the secondary role of the medial meniscus in anteroposterior restraint,¹² the lateral meniscus has been reported to be more mobile and to biomechanically serve as a secondary restraint to axial and rotatory loads.^{9,14} Qualitative and quantitative analysis of the anatomic differences between the attachments to the posterior horns of the lateral and medial menisci may provide insight into their unique roles in knee stability.

Qualitatively, we found that the posterolateral capsule attached directly to the superior margin of the PHLM. In comparison, a prior study on the posterior horn of the medial meniscus (PHMM) reported that the posteromedial capsule attached to the inferior margin at 36.4% of the total medial meniscal height.⁶ Knowledge of this difference in the depths of the capsular attachments to the posterior meniscal margins should help in the interpretation of both MRI sagittal slice interpretation and arthroscopic visualization for the assessment of vertical meniscal tears at the

TABLE 2
Distances From the Anterior and Posterior Menisiofemoral Ligament Attachments to the Posterior Horn of the Lateral Meniscus to Surgically Relevant Landmarks^a

	Posterior	Lateral	Superior
Posterolateral meniscal root attachment to aMFL	4.78	2.60	2.76
Lateral tibial eminence to aMFL	10.8	0.64	-1.09
Posterolateral meniscal root attachment to pMFL	9.19	6.89	0.79
Lateral tibial eminence to pMFL	15.7	5.32	-3.16
aMFL to pMFL	5.98	4.98	-1.78
PCL attachment to pMFL	-0.34	9.53	12.1

^aData are expressed in mm. aMFL, anterior menisiofemoral ligament; PCL, posterior cruciate ligament; pMFL, posterior menisiofemoral ligament.

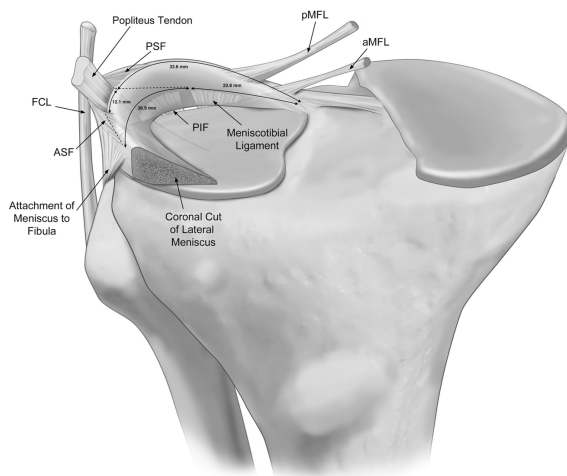


Figure 4. Anterior view illustration of the anatomic attachments to the posterolateral meniscus. The meniscotibial ligament and the posteroinferior popliteomeniscal fascicle (PIF) are depicted emerging from posterior to the lateral tibial plateau and attaching to the inferior margin of the posterolateral meniscus. aMFL, anterior menisiofemoral ligament; pMFL, posterior menisiofemoral ligament; ASF, anterosuperior popliteomeniscal fascicle; PSF, posterosuperior popliteomeniscal fascicle; FCL, fibular collateral ligament.

capsule. Furthermore, the average reported length of the posteromedial capsule attachment to the PHMM was 21.3 mm,⁶ whereas our study found that the average length of the posterolateral capsule attachment to the superior aspect of the PHLM was 16.7 mm. Although we found that the length of the lateral meniscotibial attachment to the tibia (12.8 mm) was nearly identical to the reported attachment length of the medial meniscotibial ligament (14.0 mm),⁶ these differences in the lengths of the meniscocapsular attachments to the menisci may provide insight into the etiology of the greater mobility of the lateral meniscus compared with the medial meniscus,²⁶ characterized by potentially less structural capsular restraint. Furthermore, whereas the posteromedial meniscus was constrained by attachments from the direct arm of the semimembranosus, posterior oblique ligament, and medial collateral ligament that contribute to its relative

rigidity, the increased mobility of the lateral meniscus could possibly be attributed to the larger size of the inferior popliteal hiatus, with its lack of ligamentous attachments to the lateral meniscus.

The length of the inferior popliteal hiatus was 36.9 mm along the inferior margin of the lateral meniscus, stretching from the most lateral aspect of the posterolateral meniscotibial ligament to the most anterior aspect of the anterosuperior popliteomeniscal fascicle. Therefore, this area of the lateral meniscus stretching between these structures was only restrained by the popliteomeniscal fascicles and the posterolateral capsule. This suggests that lateral meniscal repairs in this region may be potentially susceptible to overconstraint when repaired to the popliteal tendon or posterolateral capsule by the creation of a nonanatomic attachment to the lateral meniscus, possibly reducing lateral meniscal mobility over time. However, future biomechanical and long-term clinical studies evaluating lateral meniscal excursion after repair in this area are needed to determine the clinical effects of meniscal tears that are repaired to the popliteal tendon or posterolateral capsule.

Previous studies have reported on the quantitative descriptions of the popliteal hiatus and popliteomeniscal fascicles,⁵ which were validated by the quantitative measurements reported in the current study. In a previous study of the quantitative anatomy of the popliteal hiatus, Cohn and Mains⁵ reported similar quantitative descriptions of the total popliteal hiatal length (15 mm), distance from the posterior root attachment (34 mm), and length of the posterior (superior) popliteomeniscal fascicle attachment to the meniscus (9 mm). Simonnet et al²² quantified the attachments of the 3 distinct popliteomeniscal fascicles, and they also reported similar attachment lengths of the posterior (7 mm), inferior (7 mm), and anterior (5 mm) attachments. While the attachment lengths of the popliteomeniscal fascicles have been previously described, our study enhances the knowledge of these attachments by quantitatively describing their relationships to the joint line and surrounding anatomic structures, providing improved information for anatomic repairs of all 3 popliteomeniscal fascicles.

The most posterior and superior aspect of the popliteal hiatus began 33.6 mm from the posterior root of the lateral meniscus, and the inferior aspect of the popliteal hiatus began approximately 23 mm from the posterior root attachment. Arthroscopically, when assessing for tears of the

PHLM, it is important to note where the lateral meniscus and popliteal hiatus converge to avoid closing down the popliteal hiatus. Therefore, when the hiatus cannot be fully visualized, arthroscopic approximation of the distance along the superior margin of the lateral meniscus from the posterior root attachment should provide insight as to where a tear of the PHLM ends and the superior aspect of the popliteal hiatus begins. If arthroscopically identified lateral meniscal tears are measured to be near 33 mm from the posterior root of the lateral meniscus on its superior surface, further examination should be performed to evaluate if there was further extension into the popliteal hiatus, or injury to the popliteomeniscal fascicles, to avoid inadvertent closure of the popliteal hiatus during a lateral meniscal repair. Similarly, if the length of the superior popliteal hiatus exceeds 12 mm, a meniscal tear disrupting the structure of the hiatus may be present and should warrant close examination by surgical probing and assessment for a possible lateral meniscal tear.

The MFLs have been reported to play a role in limiting displacement of the PHLM,¹⁶ stabilization of the PHLM, and internal rotation of the knee.⁸ Interestingly, our study identified the aMFL in 64% of specimens and the pMFL in all specimens. Similarly, a previous cadaveric anatomy study² detailing the presence of the MFLs reported the prevalence of 75% for the aMFL, yet a slightly higher presence of 80% for the pMFL. While further clinical and biomechanical studies are needed to understand the isolated roles of the MFLs, it may be necessary to repair these structures when the MFLs are torn away in cases of vertical posterolateral meniscal tears occurring within approximately 5 to 10 mm from the center of the root attachment.

We acknowledge some limitations to this study. Only male specimens were used, which may not be generalizable to female or younger populations. Furthermore, the distal femur was sagittally sectioned to visualize the lateral meniscus and tibial plateau, which could potentially distort obtaining PHLM measurements. However, pins were placed into the native lateral meniscus to reduce the risk of soft tissue movement during data collection.

CONCLUSION

This anatomic study provides quantitative guidelines for the complex attachments to the PHLM. Knowledge of the quantitative descriptions of these attachments may aid in an improved intraoperative diagnosis of PHLM tears that extend to the popliteal hiatus, and further studies related to the surgical repair of the intricate attachments to the PHLM are recommended.

REFERENCES

1. Ahn JH, Lee SH, Kim KI, Nam J. Arthroscopic meniscus repair for recurrent subluxation of the lateral meniscus. *Knee Surg Sports Traumatol Arthrosc.* 2018;26(3):787-792.
2. Anderson CJ, Ziegler CG, Wijedicks CA, Engebretsen L, LaPrade RF. Arthroscopically pertinent anatomy of the anterolateral and

- posteromedial bundles of the posterior cruciate ligament. *J Bone Joint Surg Am.* 2012;94(21):1936-1945.
3. Arnoczky SP, Warren RF. Microvasculature of the human meniscus. *Am J Sports Med.* 1982;10(2):90-95.
4. Breitensteiner MJ, Trattnig S, Dobrocky I, et al. MR imaging of meniscal subluxation in the knee. *Acta Radiol.* 1997;38(5):876-879.
5. Cohn AK, Mains DB. Popliteal hiatus of the lateral meniscus. Anatomy and measurement at dissection of 10 specimens. *Am J Sports Med.* 1979;7(4):221-226.
6. DePhillipo NN, Moatshe G, Chahla J, et al. Quantitative and qualitative assessment of the posterior medial meniscus anatomy: defining meniscal ramp lesions. *Am J Sports Med.* 2019;47(2):372-378.
7. Diamantopoulos A, Tokis A, Tzurbakis M, Patsopoulos I, Georgoulis A. The posterolateral corner of the knee: evaluation under microsurgical dissection. *Arthroscopy.* 2005;21(7):826-833.
8. Frank JM, Moatshe G, Brady AW, et al. Lateral meniscus posterior root and menisiofemoral ligaments as stabilizing structures in the ACL-deficient knee: a biomechanical study. *Orthop J Sports Med.* 2017;5(6):2325967117695756.
9. Geeslin AG, Civitarese D, Turnbull TL, Dornan GJ, Fuso FA, LaPrade RF. Influence of lateral meniscal posterior root avulsions and the menisiofemoral ligaments on tibiofemoral contact mechanics. *Knee Surg Sports Traumatol Arthrosc.* 2016;24(5):1469-1477.
10. Horibe S, Shino K, Nakata K, Maeda A, Nakamura N, Matsumoto N. Second-look arthroscopy after meniscal repair. Review of 132 menisci repaired by an arthroscopic inside-out technique. *J Bone Joint Surg Br.* 1995;77(2):245-249.
11. LaPrade RF, Konowalchuk BK. Popliteomeniscal fascicle tears causing symptomatic lateral compartment knee pain: diagnosis by the figure-4 test and treatment by open repair. *Am J Sports Med.* 2005;33(8):1231-1236.
12. Levy IM, Torzilli PA, Warren RF. The effect of medial meniscectomy on anterior-posterior motion of the knee. *J Bone Joint Surg Am.* 1982;64(6):883-888.
13. Makdissi M, Eriksson KO, Morris HG, Young DA. MRI-negative bucket-handle tears of the lateral meniscus in athletes: a case series. *Knee Surg Sports Traumatol Arthrosc.* 2006;14(10):1012-1016.
14. Musahl V, Citak M, O'Loughlin PF, Choi D, Bedi A, Pearle AD. The effect of medial versus lateral meniscectomy on the stability of the anterior cruciate ligament-deficient knee. *Am J Sports Med.* 2010;38(8):1591-1597.
15. Ouanezar H, Blakeney WG, Latrobe C, et al. The popliteus tendon provides a safe and reliable location for all-inside meniscal repair device placement. *Knee Surg Sports Traumatol Arthrosc.* 2018;26(12):3611-3619.
16. Poynton A, Moran CJ, Moran R, O'Brien M. The menisiofemoral ligaments influence lateral meniscal motion at the human knee joint. *Arthroscopy.* 2011;27(3):365-371.e2.
17. Python Software Foundation. *Python: A Programming Language That Lets You Work Quickly and Integrate Systems More Effectively.* Wilmington, DE: Python Software Foundation; 2017.
18. Sakai H, Sasho T, Wada Y-I, et al. MRI of the popliteomeniscal fasciculi. *AJR Am J Roentgenol.* 2006;186(2):460-466.
19. Servien E, Acquitter Y, Hulet C, Seil R; French Arthroscopy Society. Lateral meniscus lesions on stable knee: a prospective multicenter study. *Orthop Traumatol Surg Res.* 2009;95(8)(suppl 1):S60-S64.
20. Simonian PT, Sussmann PS, van Trommel M, Wickiewicz TL, Warren RF. Popliteomeniscal fasciculi and lateral meniscal stability. *Am J Sports Med.* 1997;25(6):849-853.
21. Simonian PT, Sussmann PS, Wickiewicz TL, et al. Popliteomeniscal fasciculi and the unstable lateral meniscus: clinical correlation and magnetic resonance diagnosis. *Arthroscopy.* 1997;13(5):590-596.
22. Simonnet M-L, Rooze M, Feipel V. The proximal attachments of the popliteus muscle: a quantitative study and clinical significance. *Surg Radiol Anat.* 2003;25(1):58-63.
23. Stäubli HU, Birrer S. The popliteus tendon and its fascicles at the popliteal hiatus: gross anatomy and functional arthroscopic evaluation with and without anterior cruciate ligament deficiency. *Arthroscopy.* 1990;6(3):209-220.

24. Suganuma J, Mochizuki R, Inoue Y, Yamabe E, Ueda Y, Kanauchi T. Magnetic resonance imaging and arthroscopic findings of the popliteomeniscal fascicles with and without recurrent subluxation of the lateral meniscus. *Arthroscopy*. 2012;28(4):507-516.
25. Swiontkowski M, Resnick L. Getting a good grip is key to all-inside meniscal repair. *JBJS Case Connect*. 2015;5(3):e61.
26. Thompson WO, Thaete FL, Fu FH, Dye SF. Tibial meniscal dynamics using three-dimensional reconstruction of magnetic resonance images. *Am J Sports Med*. 1991;19(3):210-216.
27. Van Steyn MO, Mariscalco MW, Pedroza AD, Smerek J, Kaeding CC, Flanigan DC. The hypermobile lateral meniscus: a retrospective review of presentation, imaging, treatment, and results. *Knee Surg Sports Traumatol Arthrosc*. 2016;24(5):1555-1559.

For reprints and permission queries, please visit SAGE's Web site at <http://www.sagepub.com/journalsPermissions.nav>.